

**CHRONIC PAIN:  
*AN INTERVENTIONALIST'S  
PERSPECTIVE***

Terence K. Gray, DO  
Medical Director, Interventional Pain  
Management  
Mercy Pain Center  
*October 9, 2015*

# When Your Only Tool is a Hammer, Everything Looks Like a Nail




# TOPICS

- ▣ Low Back Pain
- ▣ Chronic headaches and cervical dystonia
- ▣ Joint Pain (knee, shoulder, hip)

# What is Low back Pain?

- Pain, muscle tension or stiffness localized below the costal margin and above the inferior gluteal folds
  - LBP with leg pain (commonly called **radicular pain**/sciatica)
  - LBP without leg pain (commonly called **axial pain**)

# LBP is designated as .....

- Acute: < 12 weeks
  - Chronic: > 12 weeks
  - Non-specific LBP
    - No recognizable pathology such as herniated disc, spinal stenosis, infection, tumor, RA, osteoporosis, or fracture.
- 

# Impact of Low Back Pain

- **Common**

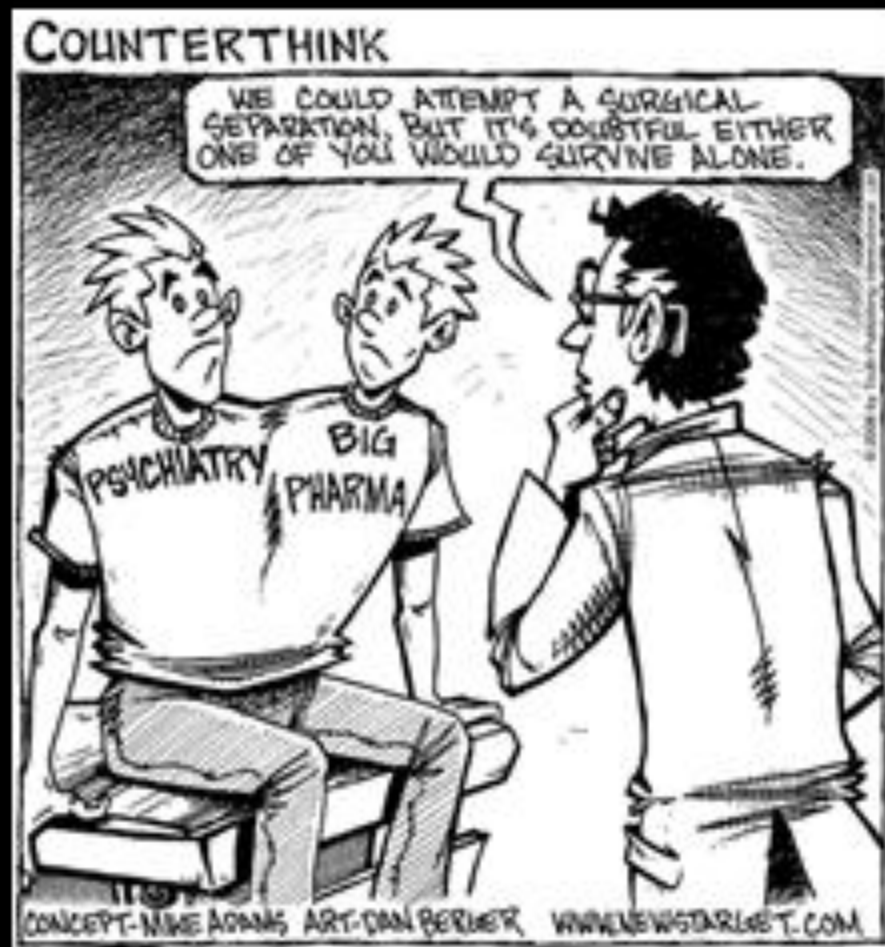- Point prevalence: 8–37%; Lifetime prevalence: 80%
- Among top 10 reasons for primary care visits –  
Comprises 40–50% of referrals to pain clinics

- **Burden of Disease (Yale-New Haven Health News):** –  
80% of adults will seek care for acute back pain at some time  
in their lives

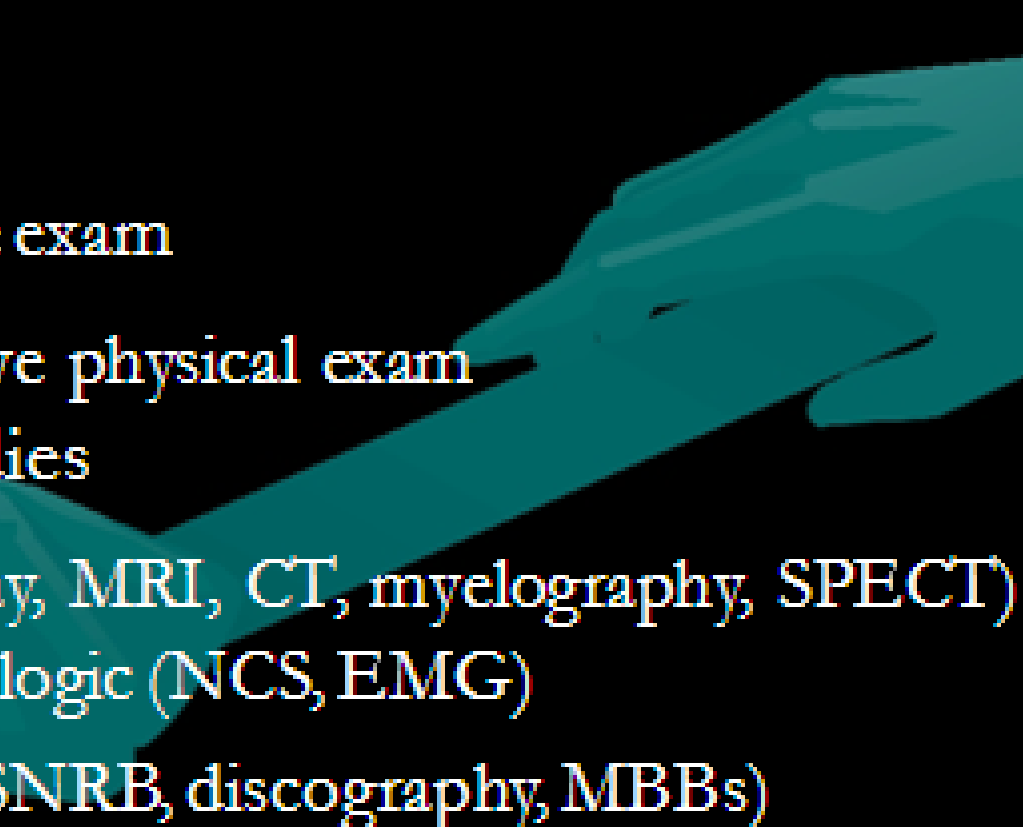
- costs now exceed 90 billion dollars each year – costs likely  
exceed well over 100 billion because the study did not  
include nursing home patients

# A Difficult Nemesis

- Relationship between organic abnormalities and dysfunction not always apparent.
- Cases complicated by psychosocial factor



# Evaluation: Basic Components

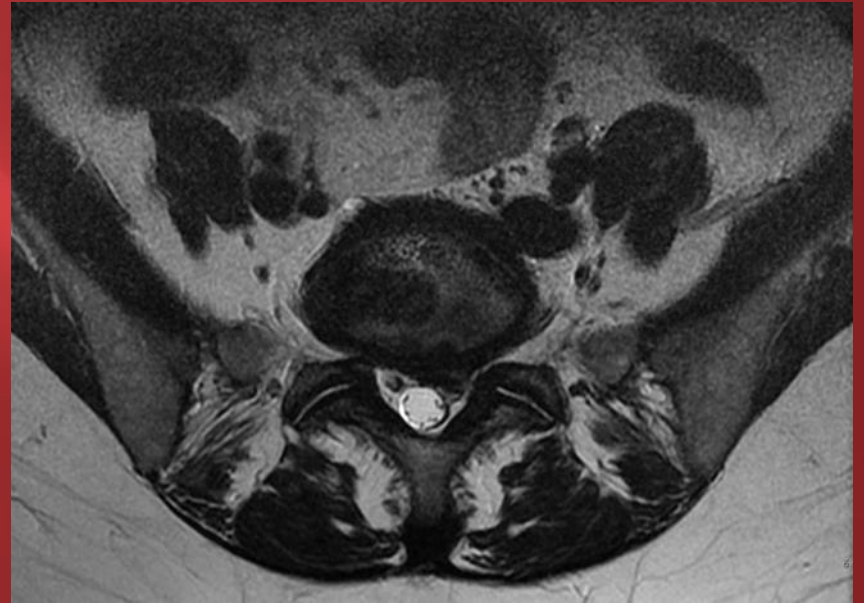
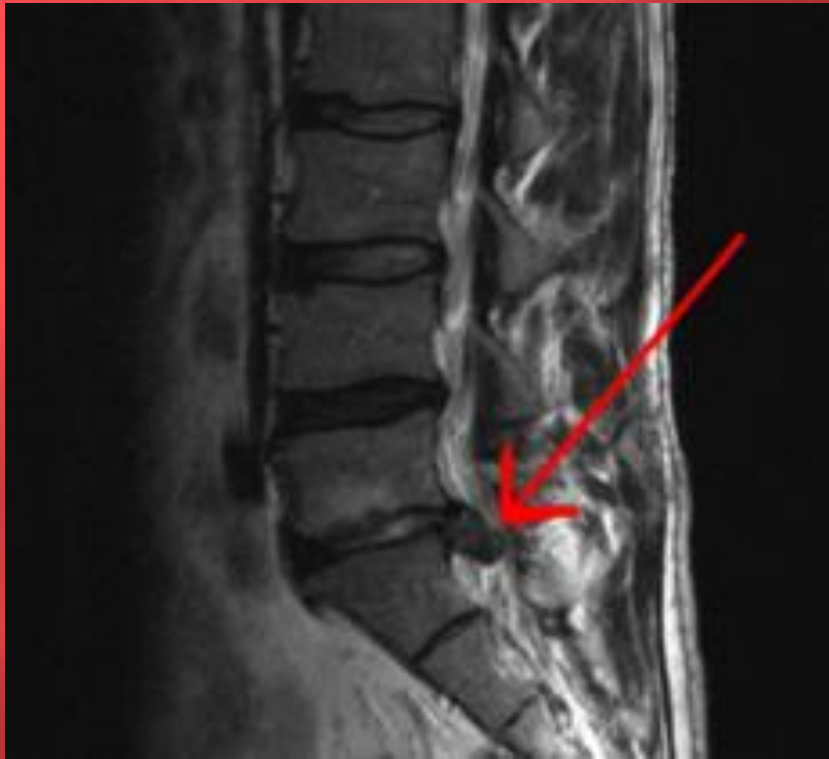- History
    - General medical history
    - Pain history
  - Physical exam
    - Focused spine exam
    - Comprehensive physical exam
  - Diagnostic studies
    - Imaging (X-ray, MRI, CT, myelography, SPECT)
    - Electrophysiologic (NCS, EMG)
    - Provocative (SNRB, discography, MBBs)
- 



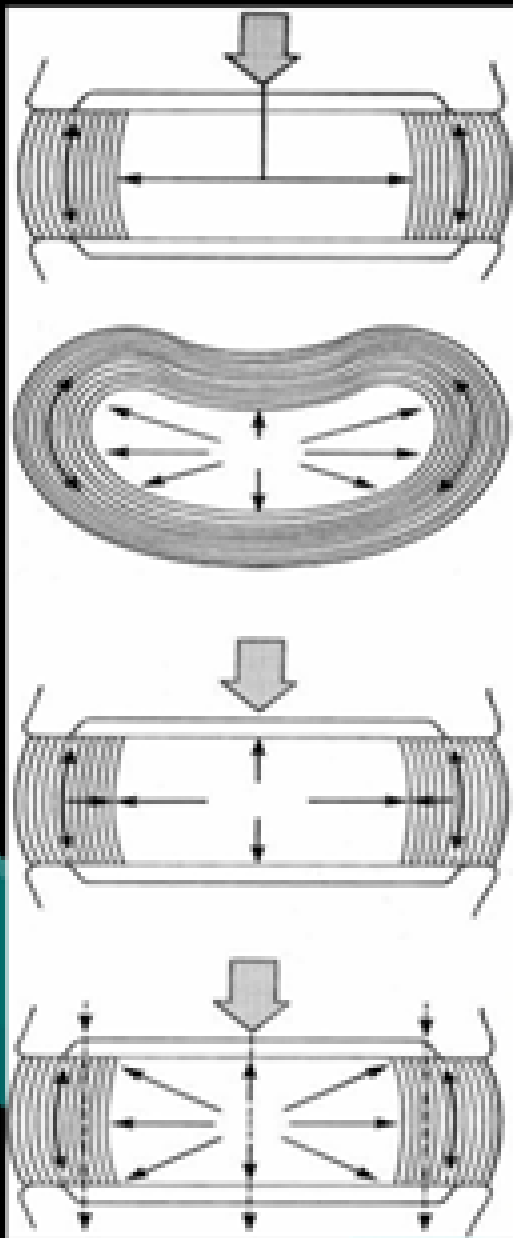
# Common Sources of Low Back And Radicular Pain

- ▣ **Herniated Intervertebral Discs/Nerve Roots**
- ▣ **Degenerative Spinal Stenosis**
- ▣ **Zygapophysial Joints (Facet Joints)**
- ▣ **Sacro Iliac Joints**
- ▣ **Piriformis Muscle**
- ▣ **Vertebral Bodies**
  - **Compression Fractures**
  - **Metastatic Tumors**

# Herniated Intervertebral Disc

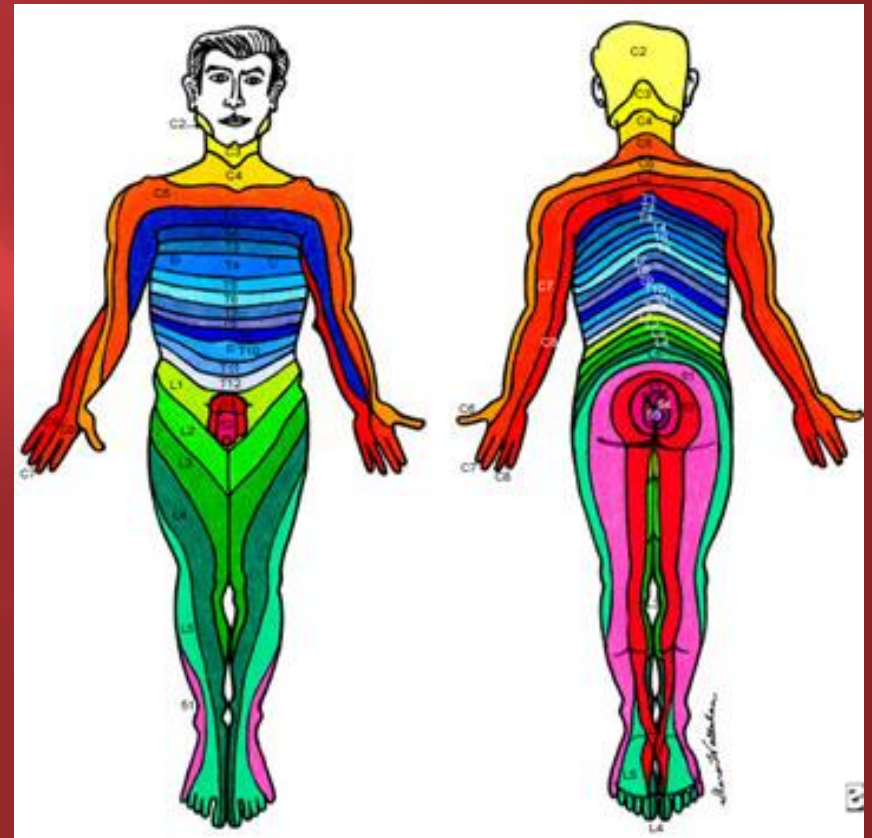
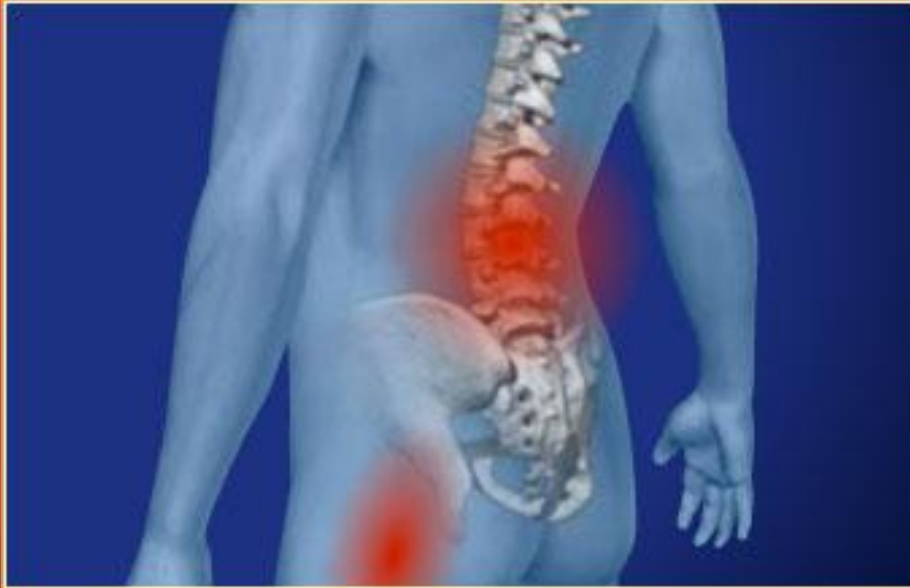


# Intervertebral Disc Pressures

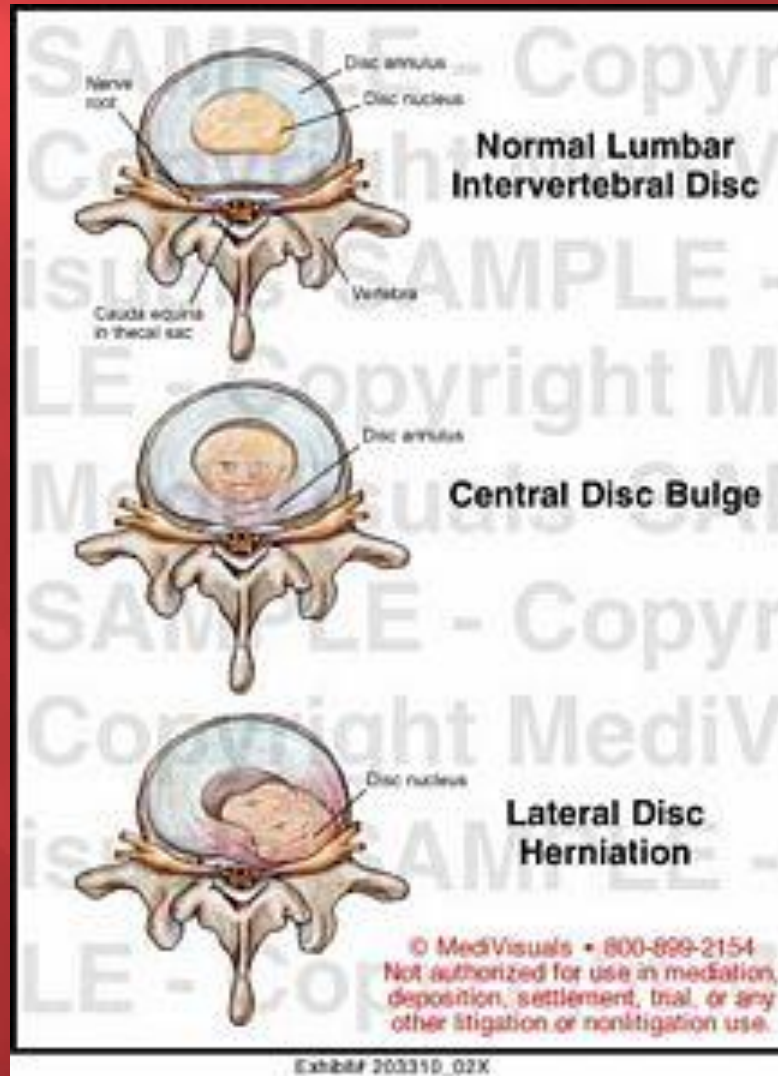


- Application of a 40 kg load to an intervertebral disc only causes 1 mm of vertical compression and 0.5 mm of radial expansion.
- Posterior disc herniations are more common because of the thinner annulus and flexion occurs more than extension.
- Posterior herniations are also more clinically significant because most of the neurovascular structures are located posteriorly.

# Discogenic Low Back Pain

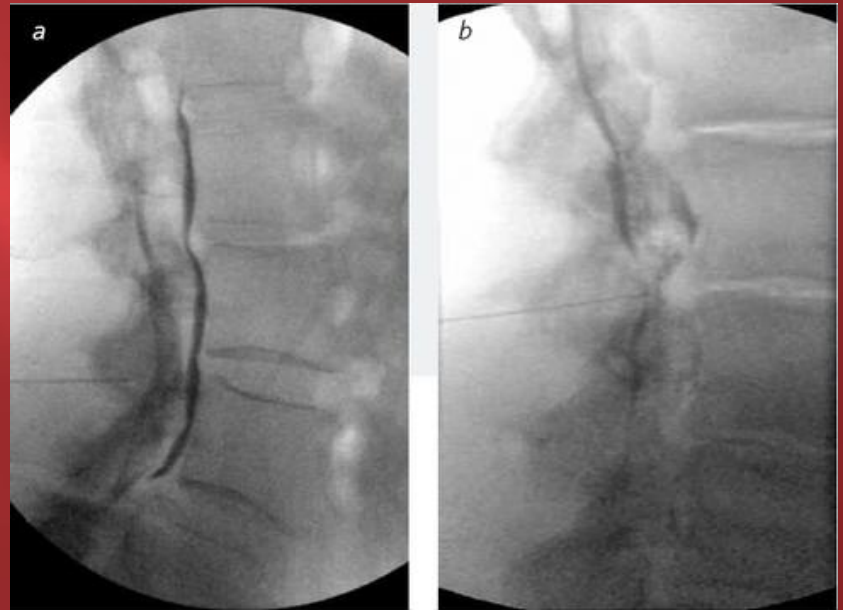
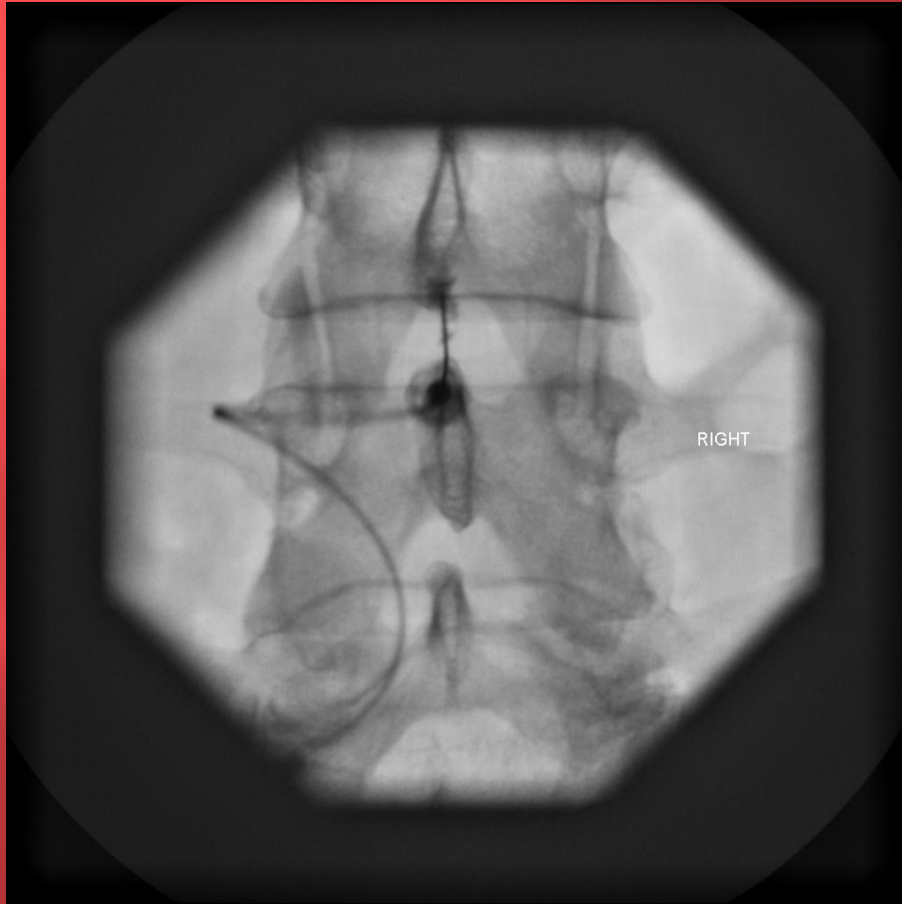


# Locations of Disc Herniations

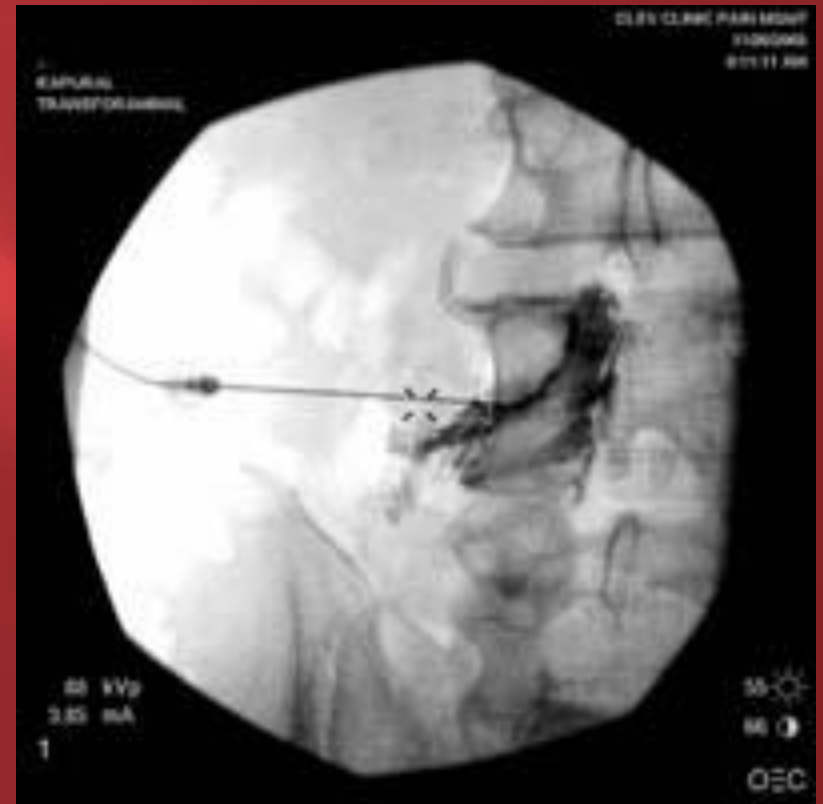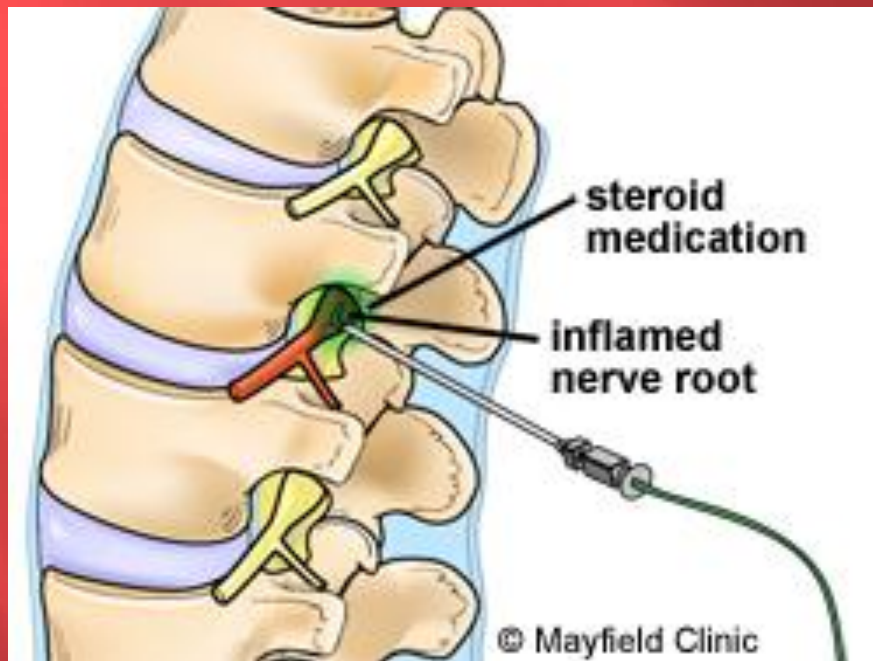




# LESI



# Transforaminal Epidural Steroid Injection (TFESI)



# Intralaminar vs. Transforaminal ESI

- Both deliver **minimal differences** in pain relief and function at 1 and 6 months
- Results indicate **both** injection types were **effective** for treating *unilateral* lumbosacral radicular pain (ULSRP).
- "These results suggest that the **difference in efficacy** between these 2 modalities **may be less significant than previously thought**,"
- It is thought that TFESI provides better results due to the **close deposition** of medication to the site of nerve entrapment .... Dr. Chang Chien said. "Yet, existing studies have shown conflicting results"
- American Academy of Pain Medicine (AAPM); March 6, 2014 ;Transforaminal vs. Interlaminar epidural steroid injections: Both offered similar pain relief, function for radiating low-back pain



# ILESI vs. TFESI

- ▣ Pain Relief:
  - At 2 weeks, TFESI had slightly better pain relief compared to ILESI
  - At 1 or 6 months, no difference in pain relief was found
- ▣ Functional Improvements
  - At 2 weeks slight superiority for ILESI (56.4%) vs. TFESI (49.4%)
  - Very slight differences for combined data (TFESI 40.1% and ILESI 44.8%)
- ▣ American Academy of Pain Medicine (AAPM); March 6, 2014 ;Transforaminal vs. Interlaminar epidural steroid injections: Both offered similar pain relief, function for radiating low-back pain

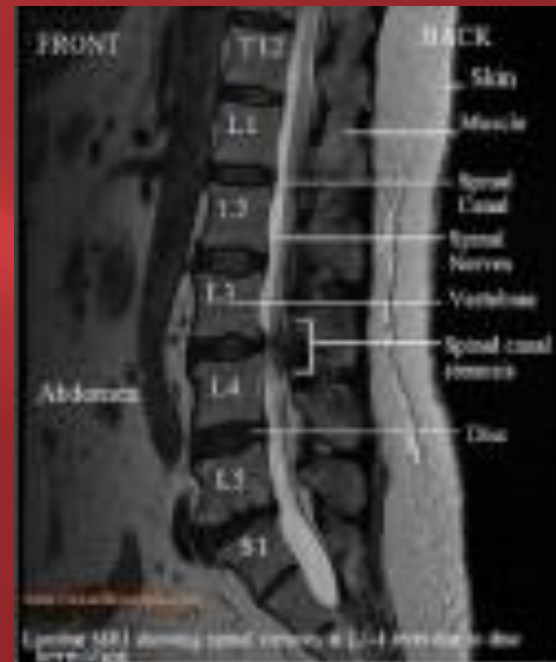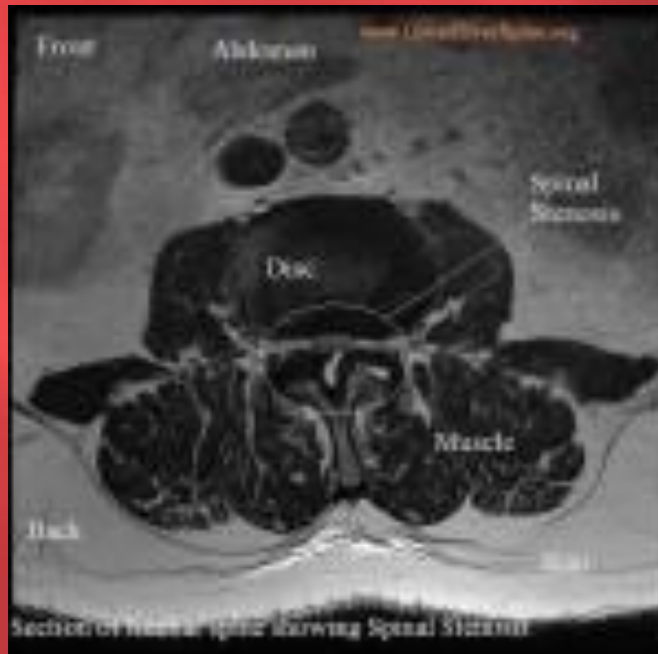
# ILESI vs. TFESI

- ▣ Trending shift away from ILESI toward the increasingly more widespread practice of the transforaminal approach (Manchikanti et al, Pain Physician 2013; 16:E349-64)
- ▣ "In part, this is due to the belief of superior efficacy,"
- ▣ "This perceived superiority of TFESI is accompanied by potential additional risks, likely to be much less common with ILESI,
  - intradiscal
  - intravascular injection with the attendant sequelae
  
- ▣ American Academy of Pain Medicine (AAPM); March 6, 2014 ;Transforaminal vs. Interlaminar epidural steroid injections: Both offered similar pain relief, function for radiating low-back pain

# ILESI vs. TFESI

- ▣ **Most complications** from epidural injections are **minor**, but **some can be serious**, including the potential for neurological damage (Chang Chien et al, Pain Physician 2012; 15: 515-23).
- ▣ This begs the **question** as to whether the increased risk of potential catastrophic morbidity is effectively offset by the minimal differences in efficacy between the 2 respective approaches
- ▣ American Academy of Pain Medicine (AAPM); March 6, 2014 ;Transforaminal vs. Interlaminar epidural steroid injections: Both offered similar pain relief, function for radiating low-back pain

# Lumbar Degenerative Spinal Stenosis



# Degenerative Spinal Stenosis

- ▣ A Randomized Trial of Epidural Glucocorticoid Injections for Spinal Stenosis
  - double-blind, multisite trial
  - **Group 1** glucocorticoid–lidocaine
  - **Group 2** lidocaine-alone
  - **400 patients** who had **lumbar central spinal stenosis and moderate-to-severe leg pain and disability**
  - The patients received **one or two injections before the primary outcome evaluation**, performed **6 weeks** after randomization and the first injection.

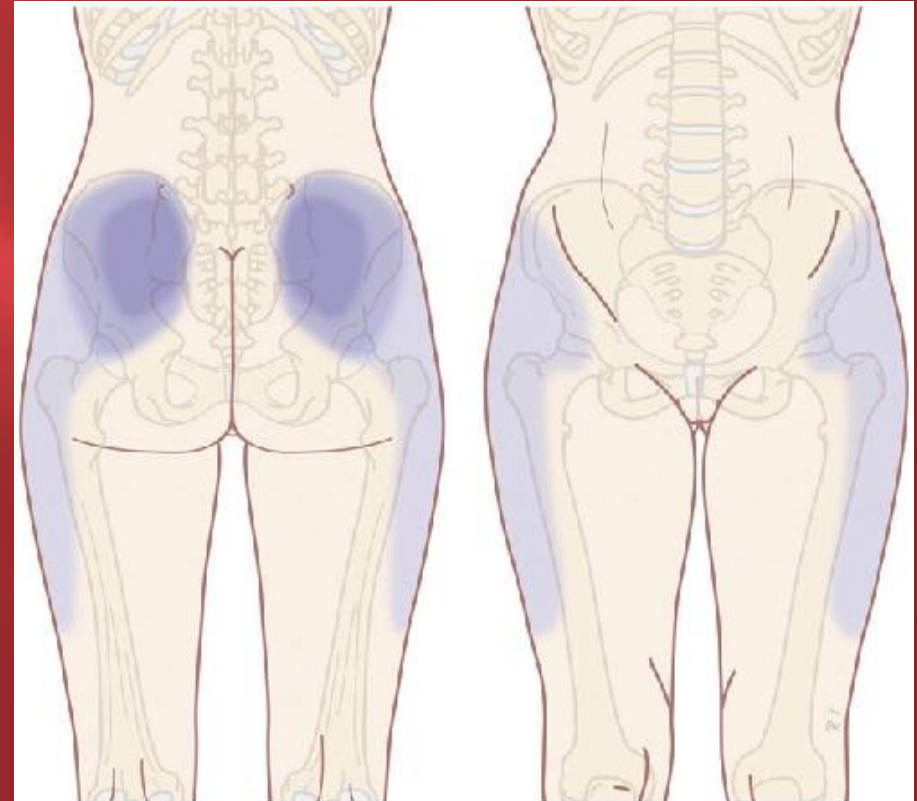
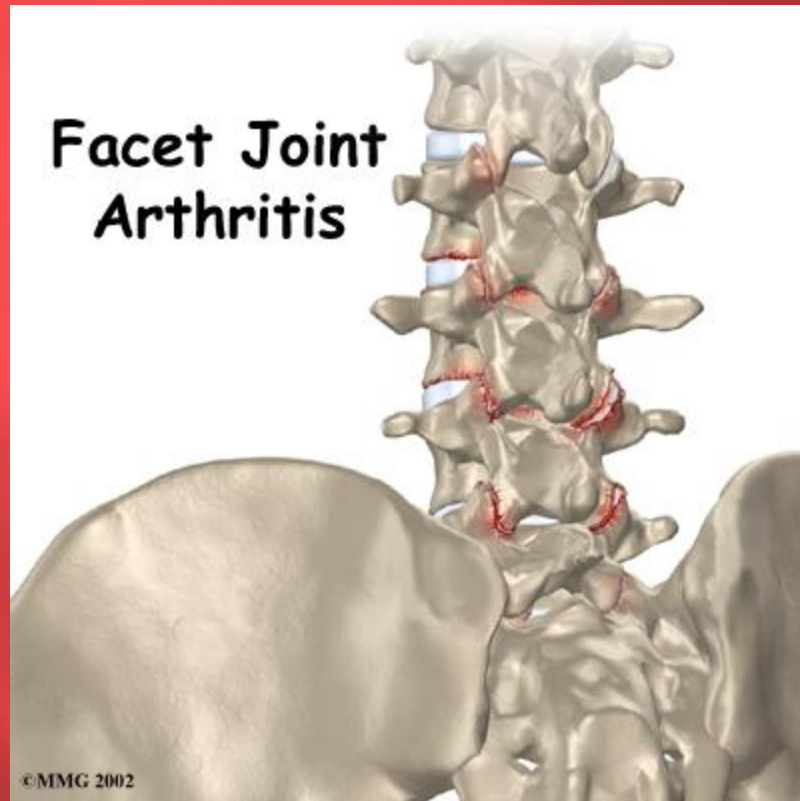
▪ N Engl J Med 2014; 371:11-21 July 3, 2014 DOI: 10.1056/NEJMoa1313265

# Degenerative Spinal Stenosis

- ▣ RESULTS:
- ▣ At 6 weeks, there were no significant between-group differences
- ▣ A prespecified secondary subgroup analysis with stratification according to type of injection (interlaminar vs. transforaminal) likewise showed no significant differences at 6 weeks.



# Lumbar Facet Mediated Pain

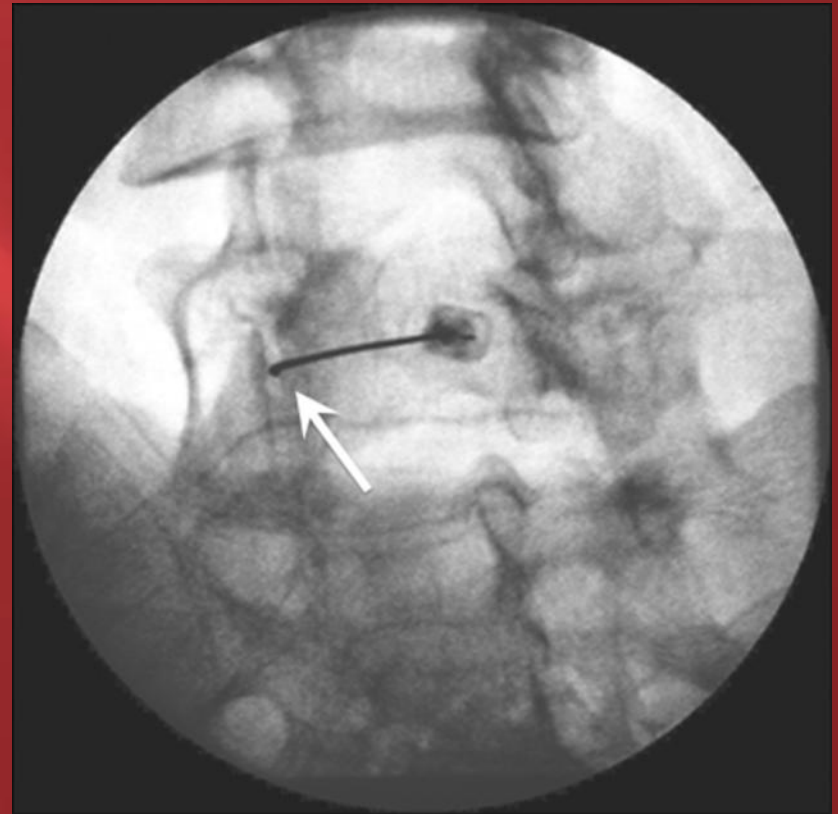
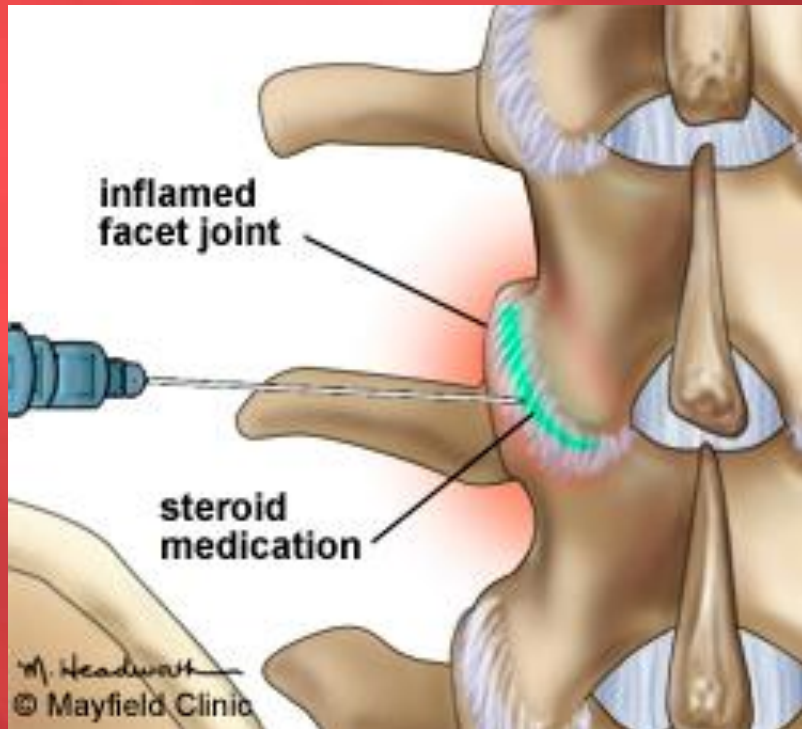


# Two Different “FACET” Injections

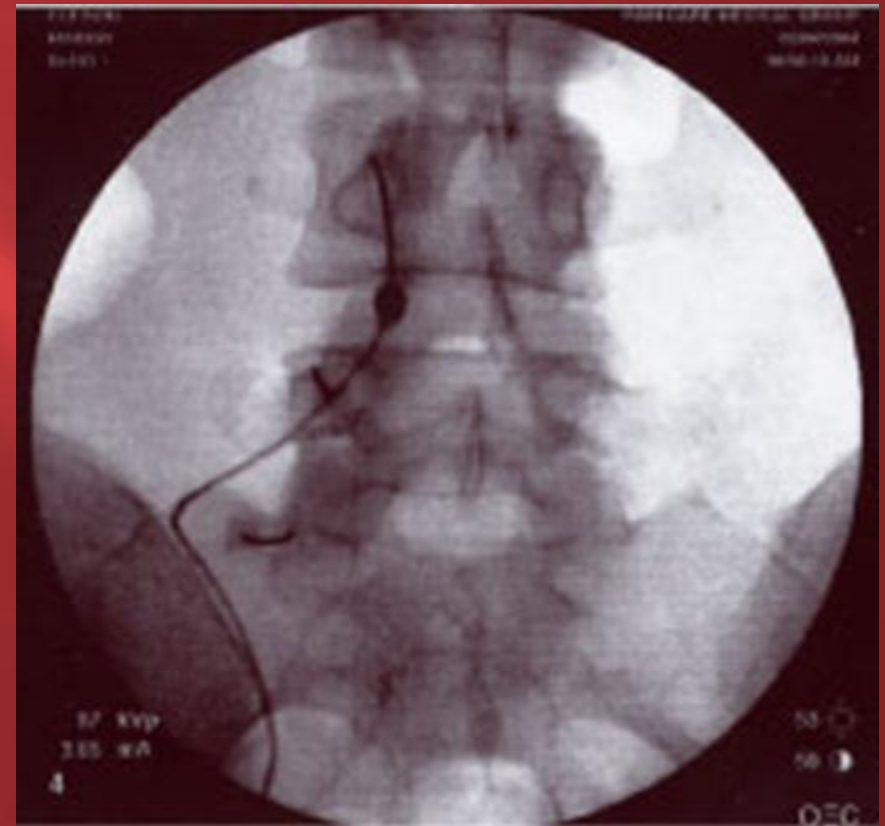
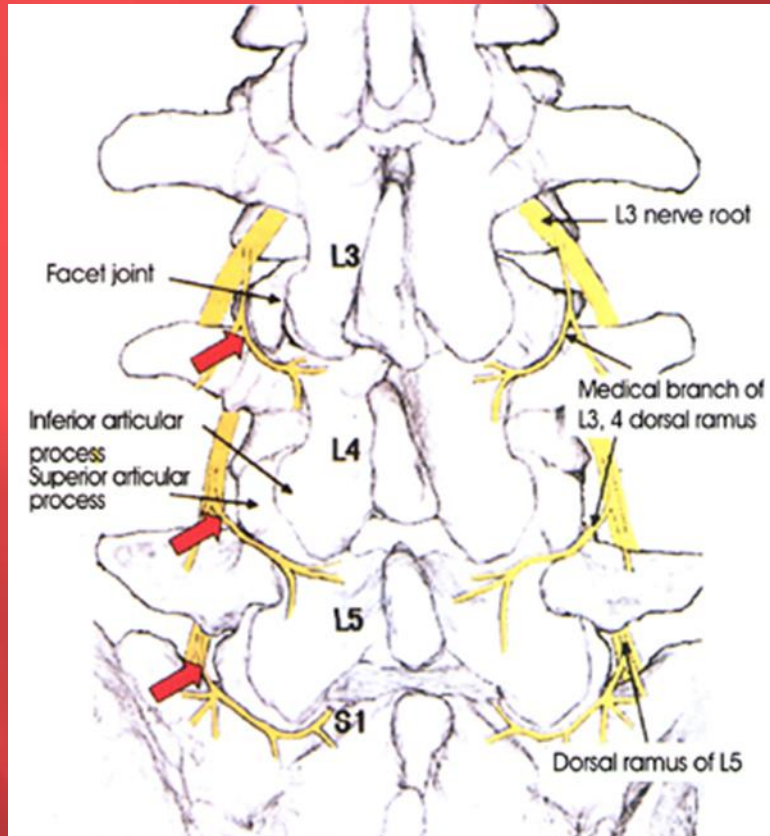
- ▣ Intra Articular Facet Joint Injection
  
- ▣ Medial Branch Nerve Block



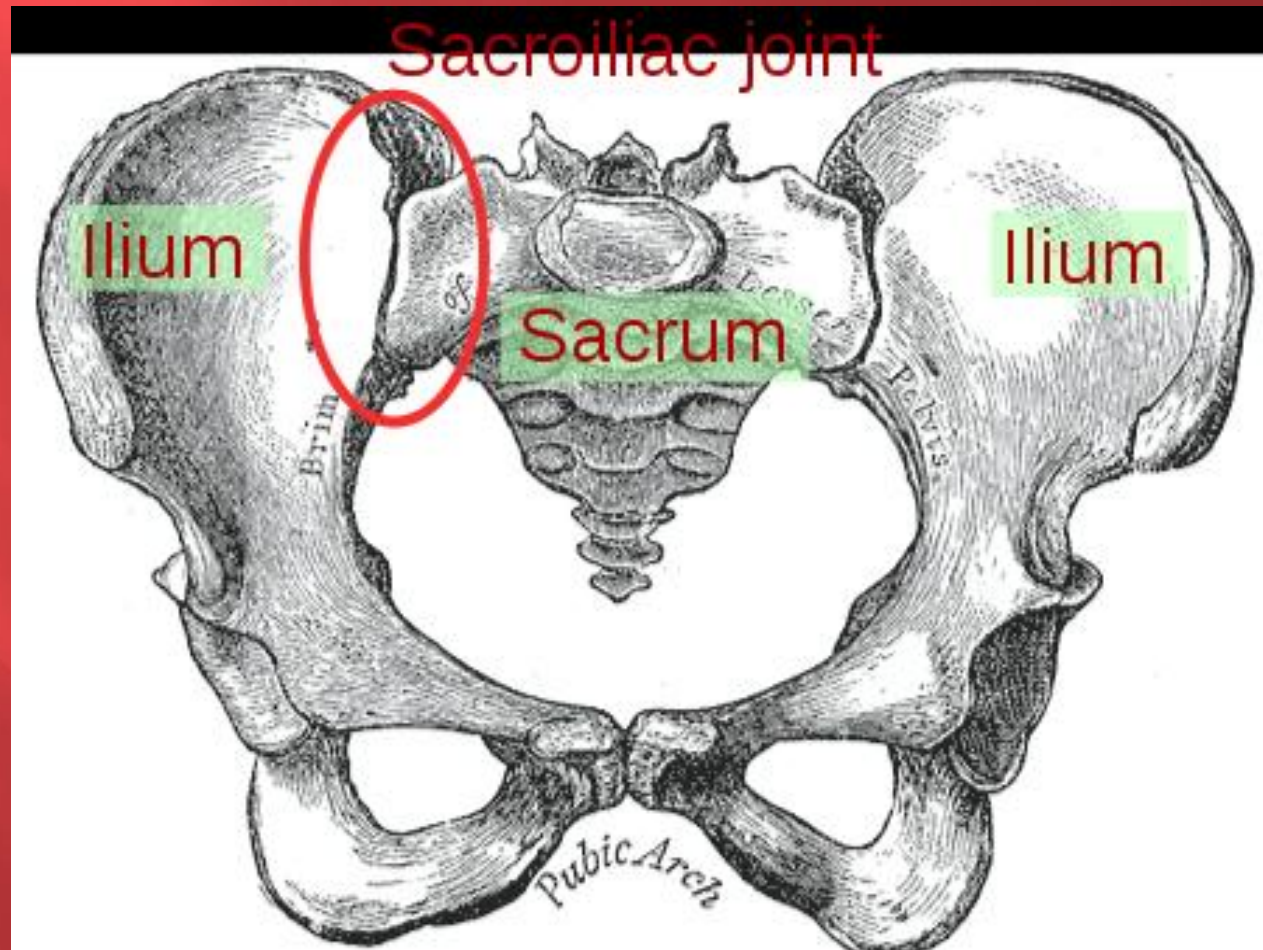
# Intrarticular Lumbar Facet Injection



# Lumbar Medial Branch Blocks



# Sacroiliac Dysfunction



# Sacroiliac Joint Pain

- ▣ Compared to the lumbar spine
  - SI joints can withstand a **medially directed** force **6 times greater**
  - **But only 50% the torsion**
  - **And only 5% of the axial compression** load.
- ▣ The SI joint is a *real* yet underappreciated pain generator in an estimated 15% to 25% of patients with axial LBP



# SI Joint Pain

- ▣ Prevalence in patients with *Chronic Low Back Pain*
  - Bernard and Kirkaldy-Willis, who found a **22.5%** prevalence rate in **1,293 adult patients** presenting with LBP
  - Schwarzer et al. conducted a prevalence study involving **43 consecutive patients with chronic LBP**. Using local anesthetic as the sole criterion for diagnosis, the prevalence of SI joint pain was found to be **30%**
  - Maigne et al. conducted a prevalence study in **54 patients** using a series of blocks done with different local anesthesia. **18.5%** were **considered to have true SI joint pain**
  - Based on these studies, the **prevalence of SI joint pain in carefully screened LBP patients appears to be in the 15-25% range.**
  
- ▣ Cohen, Steven P. Sacroiliac Anesth Analg 2005;101:1440-1453

# Mechanism of Injury of SI Joint Pain

In a retrospective by Chou et al. assessing the **inciting events** in **54 patients** with **injection-confirmed SI joint pain**, the authors found

- **trauma** (44%) of patients
- **Idiopathic** (35%)
- **Cumulative effects** of repeated stress (21%)

# Etiology of Chronic Low Back Pain in Patients Having Undergone Lumbar Fusion

Pain Medicine

Volume 12, Issue 5, pages 732-739, May 2011

- ▣ **OBJECTIVE:** To estimate the prevalence of lumbar internal disc disruption, zygapohyseal joint pain, sacroiliac joint pain, and soft tissue irritation by fusion hardware in post-fusion low back pain patients compared with non-fused patients utilizing diagnostic spinal procedures.
- ▣ **CONCLUSSION:** In patients' recalcitrant to non-interventional care, the sacroiliac joint is the most likely source of low back pain **after** lumbar fusion **followed by** internal disc disruption, zygapohyseal joint pain, and **soft tissue irritation** due to fusion hardware.
- ▣ **Sacroiliac joint pain is more common **after** fusion, while internal disc disruption is more common **in** non-fusion patients**

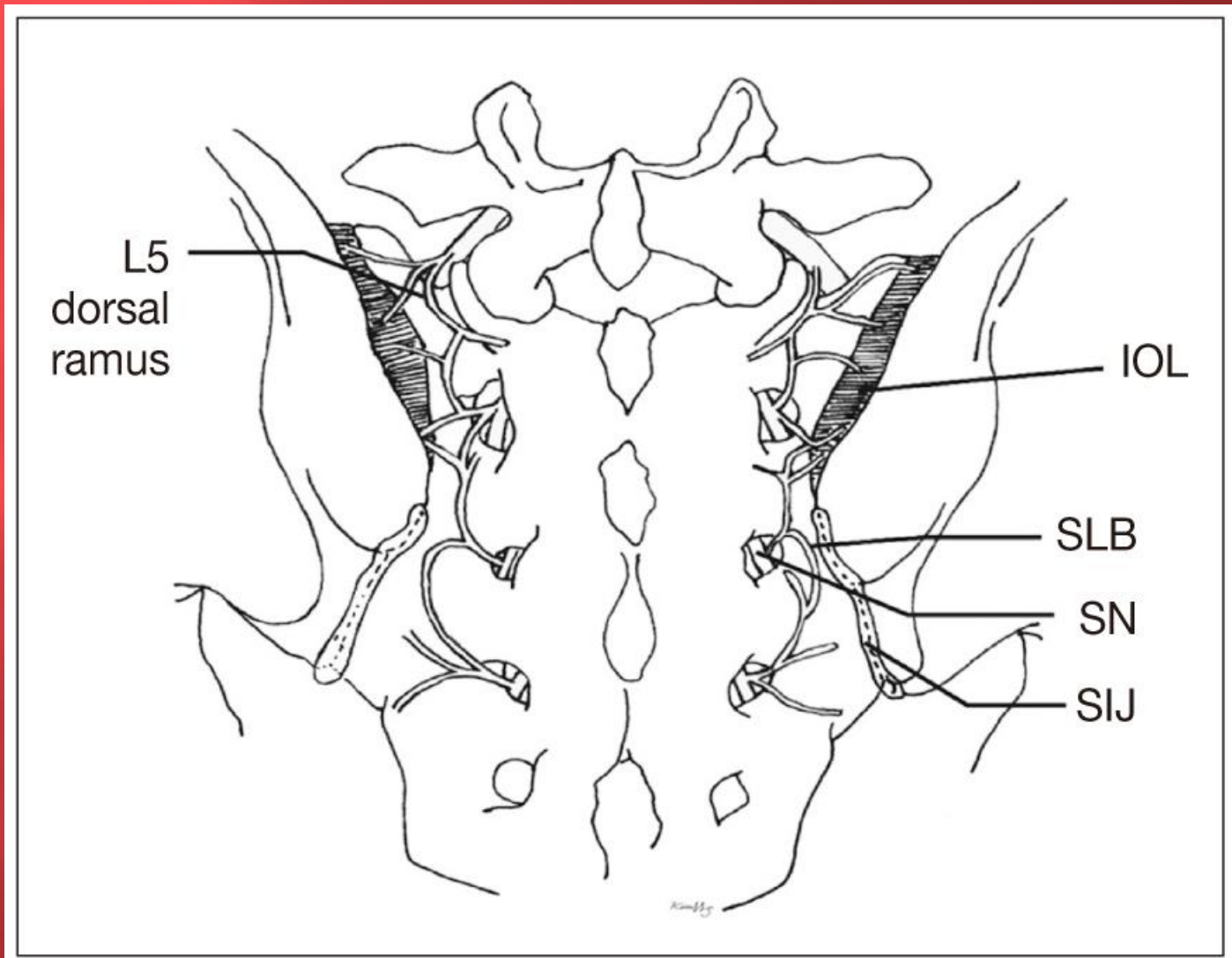
# Sacroiliac Pain

Wikipedia: Sacroiliac Joint Dysfunction

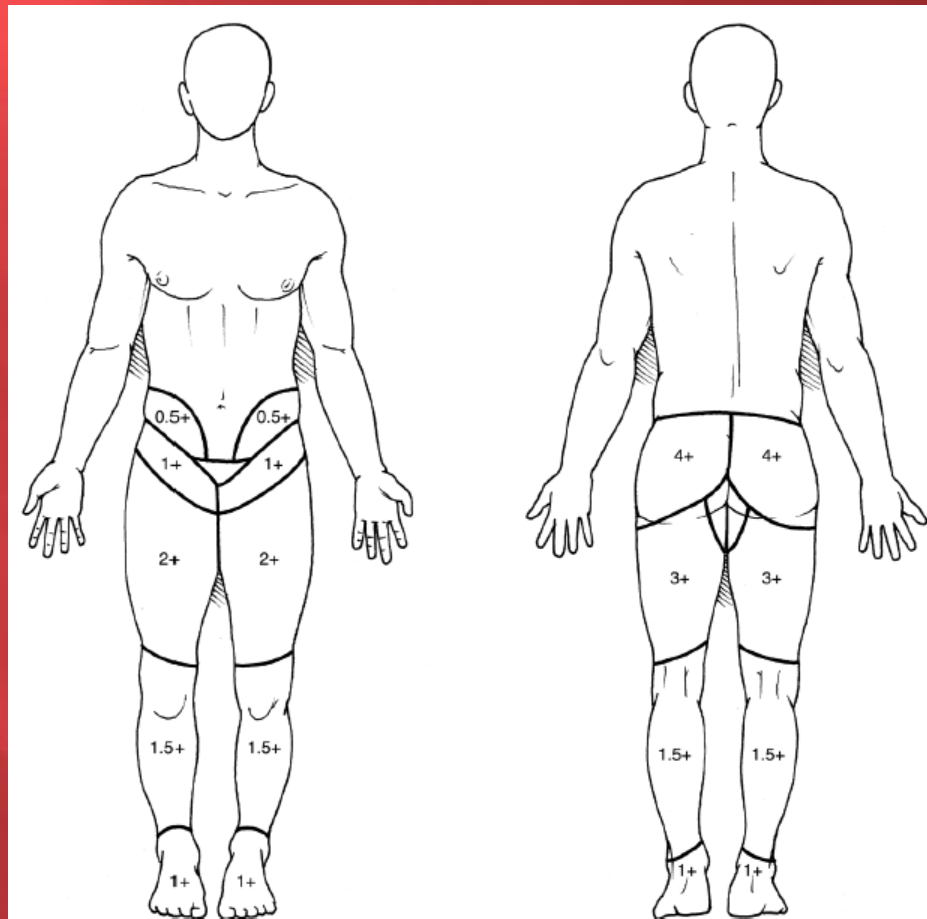
- ❑ Sacroiliac joint dysfunction or incompetence generally refers to pain in the sacroiliac joint region that is **caused by abnormal motion in the sacroiliac joint, either too much motion or too little motion**. It typically results in inflammation of the sacroiliac joint, and can be debilitating.
- ❑ **“Common symptoms include lower back pain, buttocks pain, sciatic leg pain, groin pain, hip pain, urinary frequency, and transient numbness, prickling, or tingling.”** Pain can range from dull aching to sharp and stabbing and increases with physical activity. Symptoms also worsen with prolonged or sustained positions (i.e., sitting, standing, lying). Bending forward, stair climbing, hill climbing, and rising from a seated position can also provoke pain. Pain is reported to increase during sexual intercourse and menstruation in women. Patients with severe and disabling sacroiliac joint dysfunction can suffer from insomnia and depression.



# Innervation Of Sacroiliac Joint

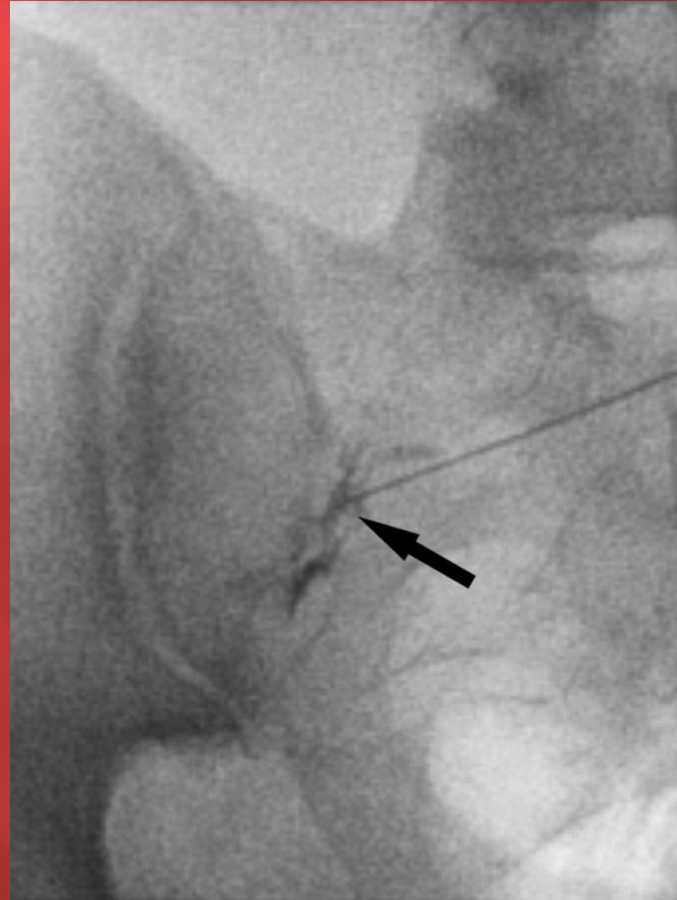


# Sacroiliac Pain Referral Pattern



**SI Joint Pain density referral zones from least common (0.5+) to most common (4+)**

# Standard SI Joint Injection





# Diagnostic Sacroiliac Joint Block via L4-5 Dorsal Rami and S1-3 Lateral Sacral Nerves



Catherine S. Monigan OMS-II<sup>1</sup>, Terence K. Gray<sup>2</sup>, DO, Frank H. Willard, PhD<sup>1</sup>

<sup>1</sup>University of New England College of Osteopathic Medicine, <sup>2</sup>Mercy Hospital, Portland, ME

## Introduction

- Sacroiliac (SI) joint pain is a relatively common ailment, with these patients comprising 13-35% of all low-back pain sufferers<sup>1,2</sup>.
- The commonly accepted standard of SI pain diagnosis is an intra-articular injection of local anesthetic<sup>3</sup>
- This diagnostic technique does not account for pain caused by the extra-articular soft tissue and ligamentous structures of the joint, which may make a significant contribution to pain in this patient population.
- Extra-articular soft tissue of the SI joint is at likely innervated by lateral sacral nerves of S1-4<sup>4</sup> and the SI joint itself has been shown to be innervated by the same lateral sacral nerves as well as branches of the dorsal rami of L4-5<sup>5</sup>.

## Hypothesis

Anesthetic block with corticosteroid of L4-5 dorsal rami and S1-3 lateral sacral nerves will confirm a diagnosis of intra-articular or extra-articular SI pain by temporarily relieving pain patterns by greater than 50% in a majority of patients.

## Materials and Methods

### Design

- IRB-approved retrospective observational study.

### Setting

- Mercy Hospital Pain Center, Portland, ME. Patient population is primarily residents of Maine with chronic pain for many years' duration.

### Participants/Subjects

- Study subjects included all patients meeting inclusion/exclusion criteria who were treated by Dr. Terence Gray at Mercy Hospital between August 2013 and June 2014.
- Inclusion Criteria: Tenderness to palpation of the sacral sulcus plus one or more positive provocative maneuvers of the SI joint including Gaenslen's test, FABERE test (with radiation to the SI joint), pelvic compression/pelvic rocking and straight leg raise.
- Exclusion Criteria: Receipt of previous injections for SI pain at Mercy Pain Center; incomplete documentation of procedures/follow-up.

### Interventions/Observations

- Patients received fluoroscopy-guided injections using a combined mixture of bupivacaine (1cc; 0.25%) and triamcinolone (6-8mg; 40mg/cc) to the dorsal rami of L4 and L5, as well as the lateral sacral branches of S1-3.
- A subset of patients (19/25) who had tenderness along the belly of the piriformis muscle also received an intramuscular injection of bupivacaine 0.25% (4cc) and triamcinolone (20mg) to the piriformis muscle belly under fluoroscopic guidance.

### Outcome Variables

- 1-10 pain score pre- and post-procedure, pain score at follow-up, all measured verbally by clinical staff.

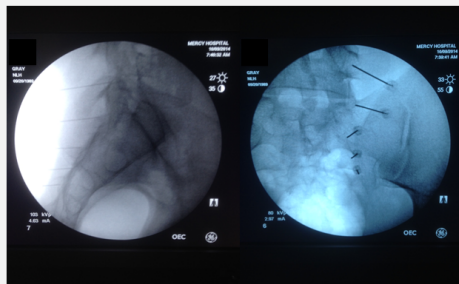


Figure 1: Lateral and A-P fluoroscopic images depicting needle placement for injection procedure.

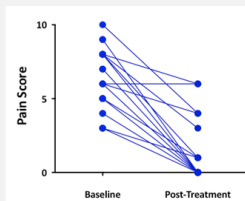


Figure 2: Change in pain score pre- and post-procedure for all participants (25).

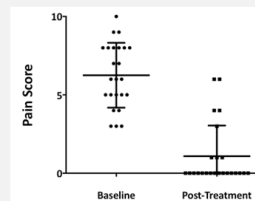


Figure 3: Pre- and post-treatment pain scores including standard error of the mean for each group.

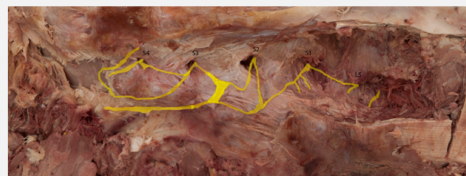

Figure 4: Cadaveric image of nerve contributions from L4 and L5 to the SI joint

## Results

- 86 injection procedures on 77 patients were performed within the designated date window. Inclusion/exclusion yielded 25 subjects, with one procedure each, for observational analysis.
- 88% (22/25) of patients had a greater than 50% reduction in their pain patterns immediately following injections. 68% (17/25) achieved 100% relief following the procedure.
- In 7 patients (28%), relief lasted through 3-4 week follow-up appointment. No significant difference was found based on laterality of treatment, sex of patient, or date of procedure (unpaired student's t-test, p<0.1)

## Conclusions

- Temporary relief of pain patterns following injection of local anesthetic suggests that the dorsal rami of L4-5 and the lateral sacral nerves of S1-3 may be responsible for pain transission in patients suffering from SI pain
- Return of symptoms within days-weeks of the procedure for a majority of patients suggests that injections alone are likely not a viable long-term treatment option, but that this procedure may serve as a useful diagnostic test.
- Further evaluation is needed to verify the present results.

## Future Directions

Radiofrequency ablation of dorsal rami of L4-5 and lateral sacral nerves of S1-3 may be a viable long-term treatment for SI pain, with the present injection protocol serving as a powerful predictor of procedure success.

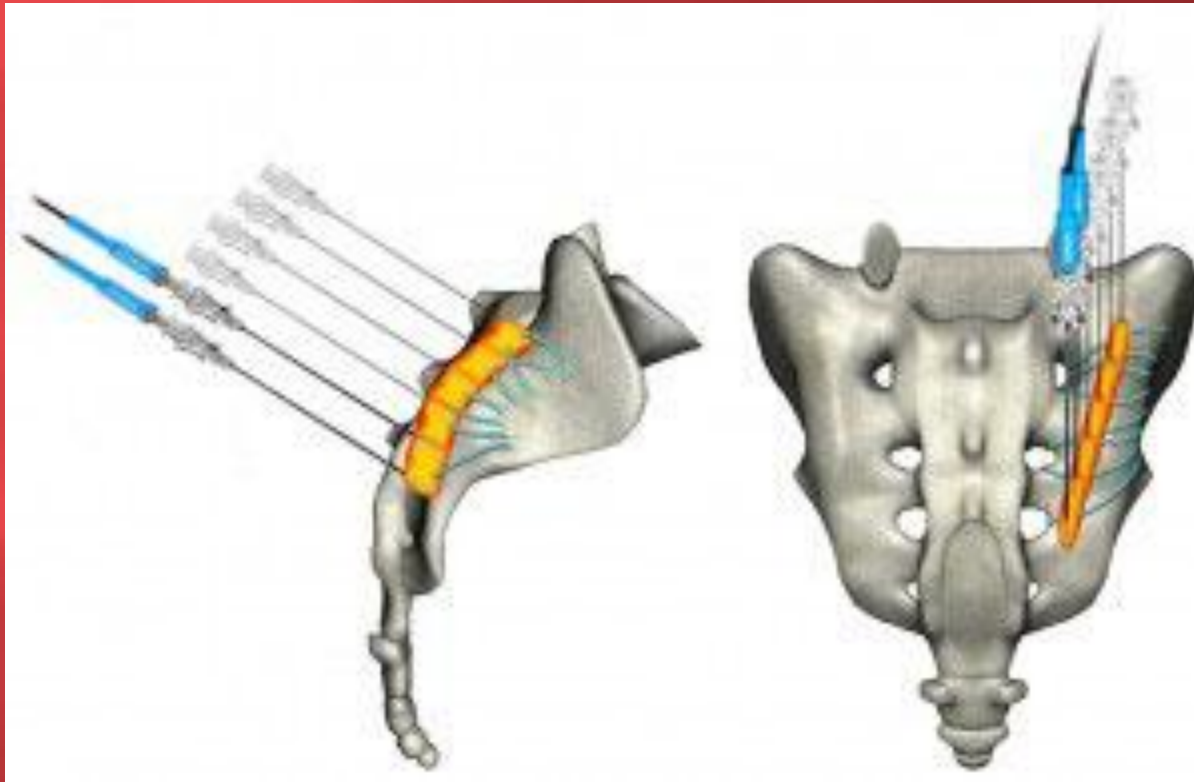
## Acknowledgements

This research was sponsored by the University of New England Center for Excellence in Neuroscience Research Fellowship. Sincere thanks to Dr. Edward Bilsky for his introductions, advice, and assistance with statistics, and to Joel Talsma for his meticulous dissection.

## References

- Katz V, Schofferman J, Reynolds J. The sacroiliac joint: a potential cause of pain after lumbar fusion to the sacrum. J Spinal Disord Tech. 2003 Feb;16(1):96-9.
- Maigne JV, Avallakis A, Pfefer F. Results of sacroiliac joint double block and value of sacroiliac pain provocation tests in 54 patients with low back pain. Spine (Phila Pa 1976). 1996 Aug 15;21(16):1889-92.
- Bogduk N. Practice Guidelines for Spinal Diagnostic and Treatment Procedures: Sacroiliac Joint Blocks. Kentfield, CA: International Spine Intervention Society; 2004. 66-85
- MicGrosh MC, Zhang M. Lateral branches of dorsal sacral nerve plexus and the long posterior sacroiliac ligament. Surg Radiol Anat. 2005 Nov;27(4):327-30. Epub 2005 Nov 9.
- Forst SL, Wheeler MT, Fortin JD, Vilensky JA. The sacroiliac joint: anatomy, physiology and clinical significance. Pain Physician. 2006 Jan;9(1):61-7.

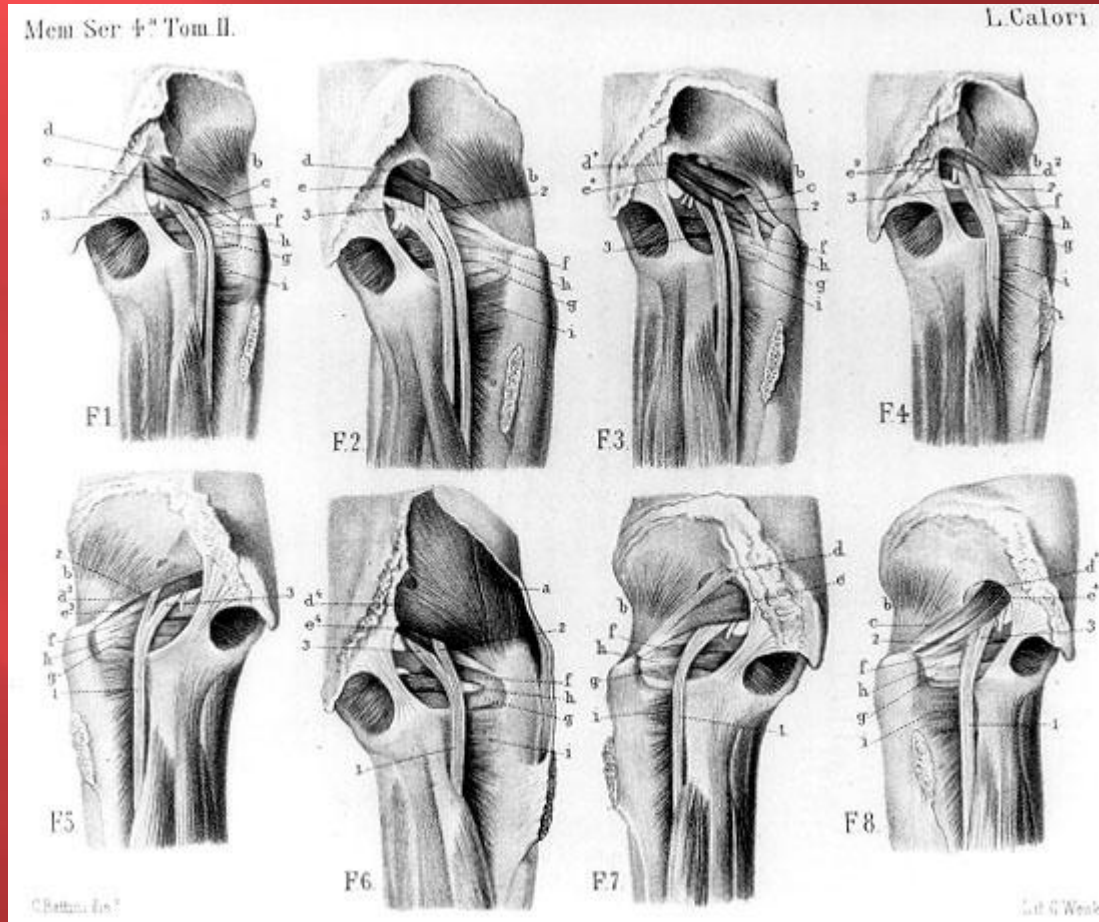
# Newer SI Joint Injection Technique





# Piriformis Muscle Pain

Illustrated Encyclopedia of Human Anatomic Variation: Opus III: Nervous System Variations in Sciatic Nerve. (Variations in M. Piriformis).

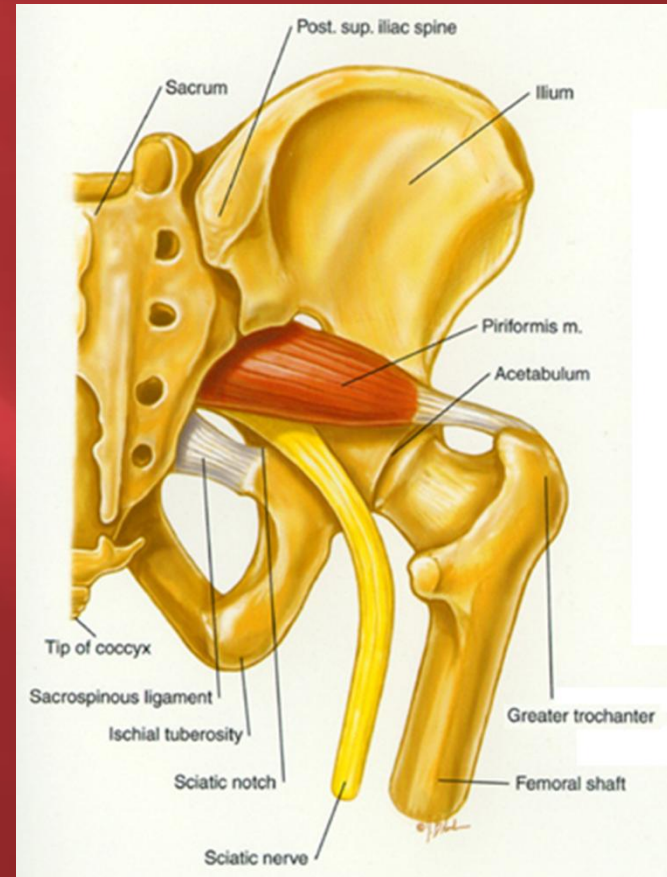
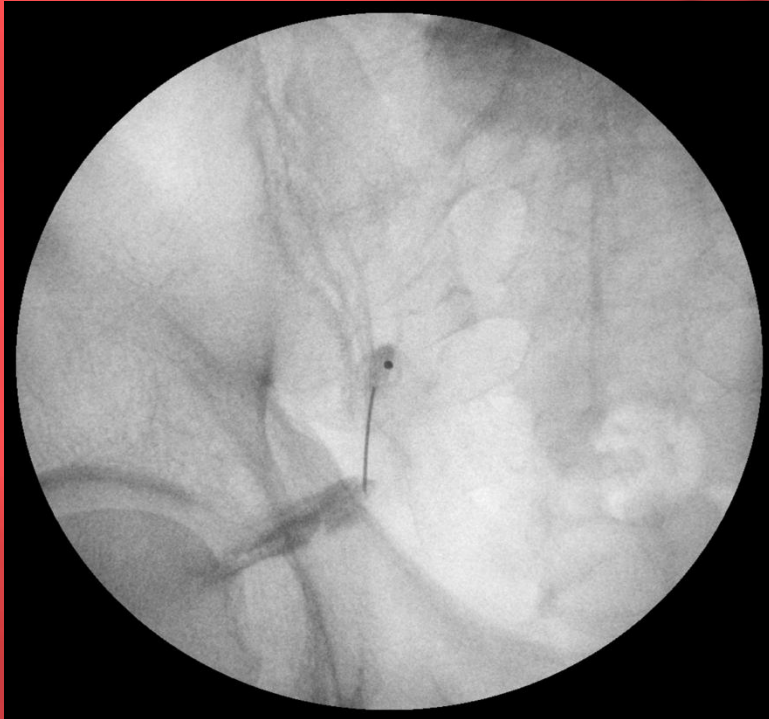




# A New Technique for Fluoroscopic Guided Piriformis Injection:

- ▣ A Case Report of Successful Relief of Piriformis Syndrome in the Boston VA Healthcare System  
Cheema, S.P.K. (1) Andima, L. (1) Michna, E. (2)
- ▣ (1) VA Boston Healthcare System, Harvard School of Medicine  
(2) Brigham and Women's Hospital, Harvard School of Medicine

# Piriformis Injection Sacral Approach



# Piriformis Muscle Injection Sacral Approach

- Originates from the anterior surface of the sacrum and inserts into the superior aspect of the greater trochanter of the femur.
  
- In this technique:
  - Fluoroscopic visualization of the inferior edge of the sacroiliac joint
  - 22 g spinal needle advanced perpendicular to the joint
  - The depth of needle was marked, then retracted back until close to the skin
  - Reangled at a 45 degree angle lateral and caudal direction, up to the aforementioned marked depth
  - Anatomic identification of the piriformis muscle confirmed with radiopaque contrast medium and fluoroscopic imaging.
  - A mixture of 20 mg-40 mg of Triamcinolone in 4 cc of 0.25% bupivacaine/1% Lidocaine or mixture of both was then administered
  - Refractory Piriformis pain MAY be treated with Botox for longer effect

# Chronic Daily Headache

- ▣ Causes of chronic daily headaches aren't well-understood.
- ▣ True (*primary*) chronic daily headaches don't have an identifiable underlying cause.
- ▣ Conditions that may cause *non-primary* chronic daily headaches include:
  - *Inflammation* or other *problems with the blood vessels* in and around the brain, including stroke
  - *Infections*, such as meningitis
  - *Intracranial pressure* that's either *too high or too low*
  - *Brain tumor*
  - *Traumatic brain injury*

# MEDICATION OVERUSE HEADACHE

- ▣ Usually develops in people who have an **episodic headache disorder** (usually migraine or tension-type)
- ▣ Take **too much** pain medication **too frequently**.
  - If you're **taking pain medications** — even over-the-counter analgesics — **more than two days a week** (or **nine days a month**), you're **at risk** of developing rebound headaches

# OCCIPITAL NEURALGIA

- ▣ Defined by the International Committee for Headache Disorders (ICHD-III) as *unilateral or bilateral* pain in the distribution of the greater, lesser, and/or third occipital nerves.
- ▣ Occipital neuralgia is **usually** idiopathic, but is **also** considered a **common form of posttraumatic headache**



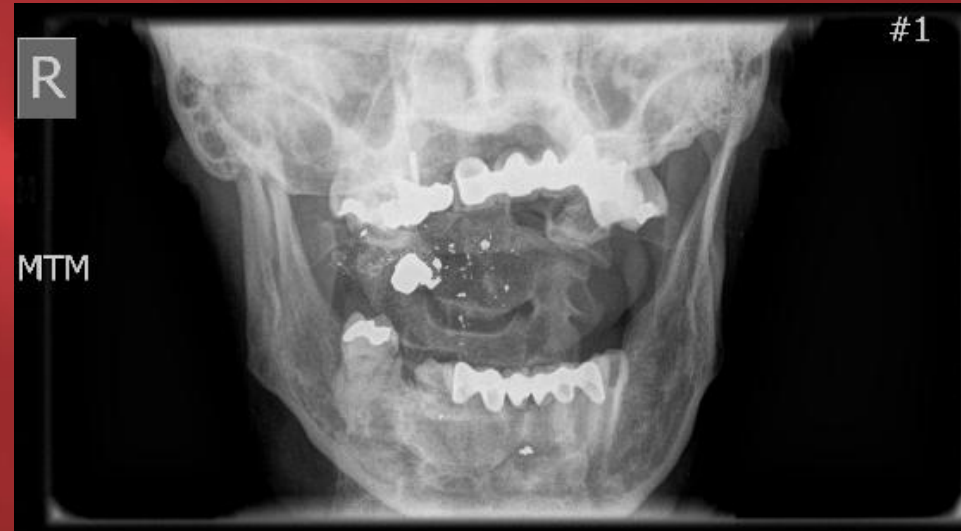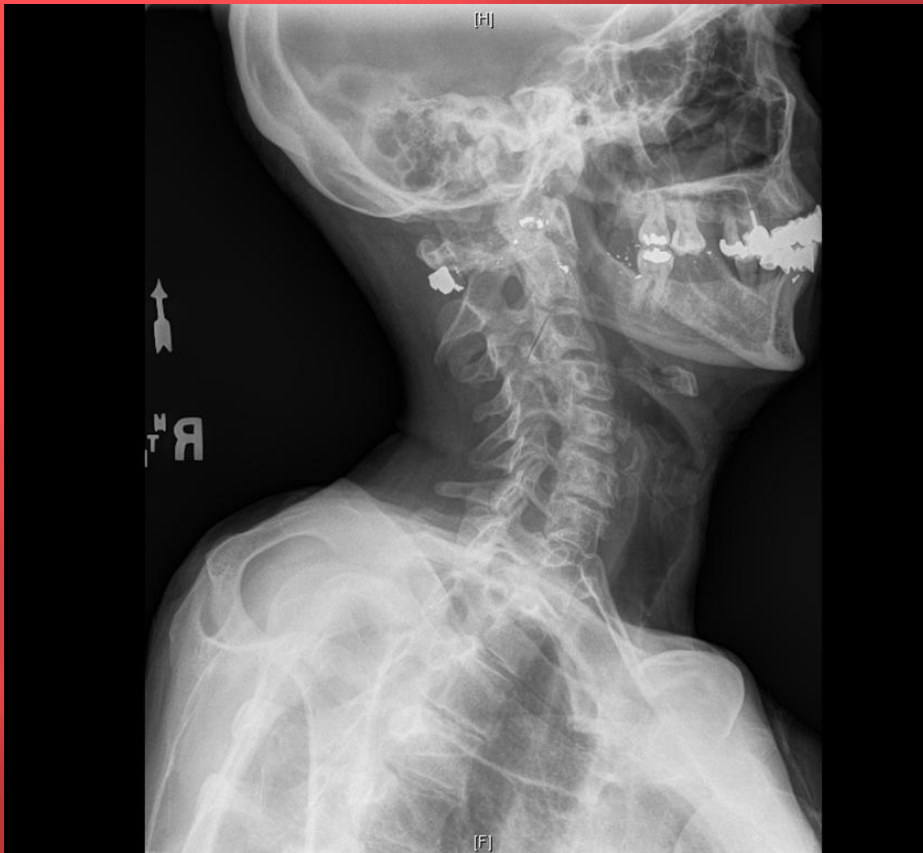# OCCIPITAL NEURALGIA

- ▣ “C2 neuralgia” or (rarely) “Arnold's neuralgia”
- ▣ Characterized by chronic pain in the”
  - upper neck
  - back of the head
  - Around the temples
  - behind the eyes.
  - These areas correspond to the locations of the greater, lesser and third occipital nerves.
- ▣ The greater occipital nerve also has an artery that supplies blood that is wrapped around it - the occipital artery - that can contribute to the neuralgia. This condition is also sometimes characterized by diminished sensation in the affected area as well.

# Case Report

- ▣ A 50 year-old Caucasian female presented for initial evaluation with a 14-month history of pain in the right occiput radiating to the top of the right scalp. Pain was described as constant and throbbing, and rated as a 5 using the Visual Analog Scale (VAS) for pain. Secondary complaints include several tender points over the patient's right scapula, right arm weakness, and intermittent numbness and tingling in all digits bilaterally. The patient sustained a gunshot wound through the mouth 14 months earlier, fracturing the 1st cervical vertebra (C1) and leading to right vertebral artery dissection and aneurysm following stent placement. Cervical spine flexion and

# Occipital Neuralgia Case



# Case Report

- extension x-rays taken 3 months after the injury revealed evidence of comminuted C1 fracture and mild anterolisthesis of C2 on C3 upon flexion. Previous **unsuccessful treatments included physical therapy, acupuncture, application of heat, and lidocaine injections in the right shoulder and neck.** Pain medications prescribed prior to evaluation included aspirin 81 mg, gabapentin 300+600 mg, and oxycodone HCl 5 mg.
- Diagnostic nerve blocks with local anesthetic were performed 3 weeks later. **A total of 3 ml of 0.25 bupivacaine and 3ml of 1% lidocaine plus 40 mg triamcinolone was injected into the right greater and lesser occipital nerves and the right auriculotemporal nerve. The patient reported a VAS score of 7 prior to injection, which decreased to 2 immediately following treatment.**
- Upon **follow-up 1 month later**, she reported a **VAS score of 5**, reporting a **25% overall improvement** in pain and functionality. **Slightly greater than 50% relief was experienced for several weeks**; the patient stated this to be the **first period of pain relief since her injury**. A diagnosis of occipital neuralgia was made based on ICHD-III criteria, including severe paroxysmal pain in the distribution of the greater and lesser occipital nerves, tenderness over the affected nerves, and temporary pain relief by local anesthetic block.<sup>1</sup>

# Case Report

- **Right occipital and auriculotemporal nerve blocks were repeated after another 3 weeks, leading to a VAS score decrease from 7 to 0 following treatment.** The patient reported **100% relief for 3 days during follow-up**, with an overall improvement of 70% in right occiput and lateral neck, and 30% in the right parietal area. Stated VAS scores in the right occipital and right parietal areas were 1 and 4, respectively. The decision was made to progress to BTX-A treatment.
- **Occipital nerve blocks with botulinum toxin A were performed 4 months after initial evaluation.** 120 units of Botox were equally divided among 24 injection points, along the trapezius, occipitalis, temporalis, and cervical paraspinal muscles bilaterally. The patient reported immediate pain relief, from a pre-procedure VAS score of 5 to 0 post-procedure. Upon follow-up 1 month later, the patient stated that the BTX-A injections “were different” than previous treatment with local anesthetic, leading to complete resolution in the pain on the top and right side of her skull, in addition to her right shoulder, neck and arm. The only remaining pain was experienced in the right occiput in a 2-3 cm diameter, with a pain score of 3. **The patient reported an overall improvement in symptoms of 80-90%, stating, “this is the closest to normal I have ever been”.** An additional follow-up after 4-6 weeks was recommended.



# Botulinum toxin nerve blocks in the treatment of occipital neuralgia

Andrew Ea MS, Terence Gray DO

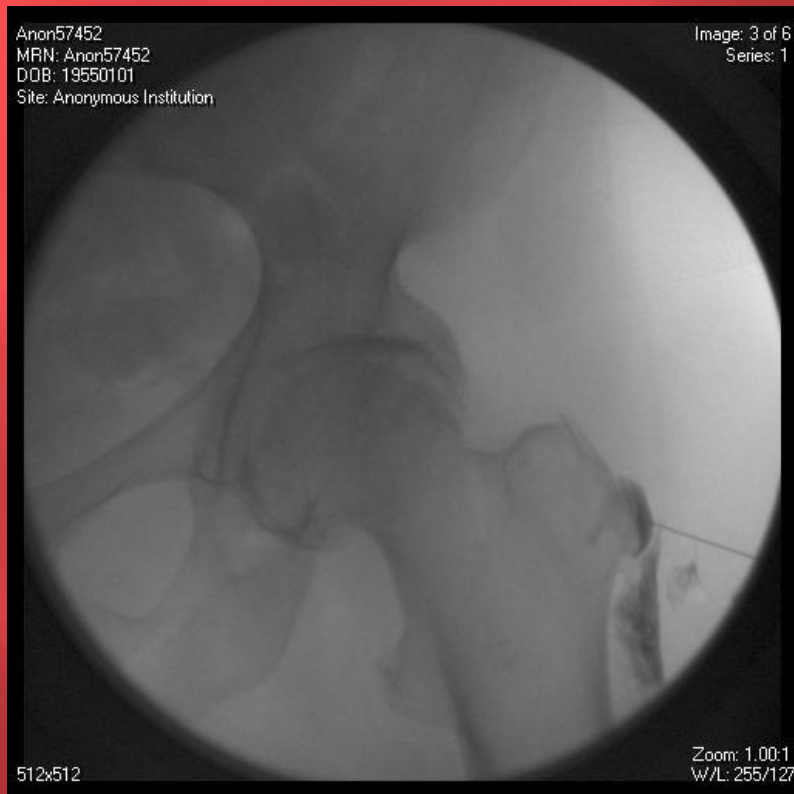
- ▣ Mean overall relief was  $75.8 \pm 25.0\%$ . Treatment with local anesthetic suggested **equally efficacious** reduction of VAS scores; however, treatment with **BTX-A** showed a **significantly higher percentage of overall pain relief** leading to follow-up.
- ▣ Our results **support the hypothesis** that use of **Botulinum toxin A** in occipital nerve blocks leads to **significant decreases in pain**, while possibly **exhibiting a longer duration of action** than that of local anesthetic.



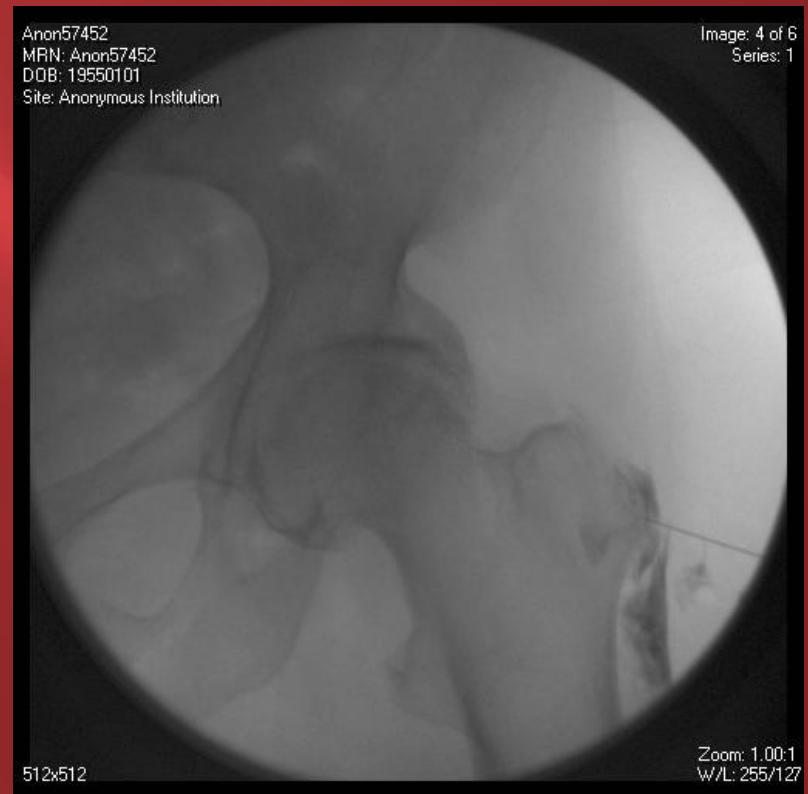- Our study retrospectively examined 63 patients treated for occipital neuralgia, including 19 with BTX-A. 80-155 units of BTX-A were administered bilaterally in the surrounding musculature. A total of 61 patients, including 17 of those subsequently treated with BTX-A, were treated with local anesthetic, using a 1:1 mixture of 0.25% bupivacaine and 1% lidocaine, plus triamcinolone. Patients reported VAS pain scores before and after their procedures, and again during 4-week follow-up visits. Information on opioid use, overall pain relief, and duration of full relief was also recorded upon follow-up.
- Comparison of overall pain relief in the 17 patients treated in our clinic with local anesthetic followed by BTX-A did not show a significant difference between treatments ( $p = 0.0543$ ). However, when compared to the average pain relief of all patients receiving local anesthetic, treatment with BTX-A showed a significantly higher percentage of pain relief upon follow-up ( $p = 0.0126$ ).

# TROCHANTERIC BURSA INJECTIONS

## PRE-INJECTION

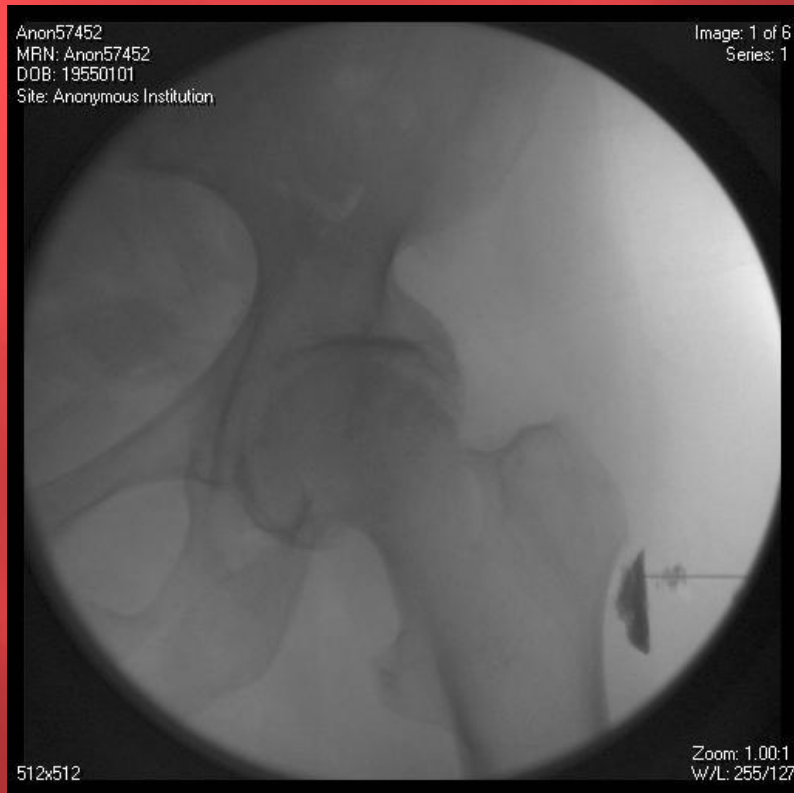


## POST-INJECTION

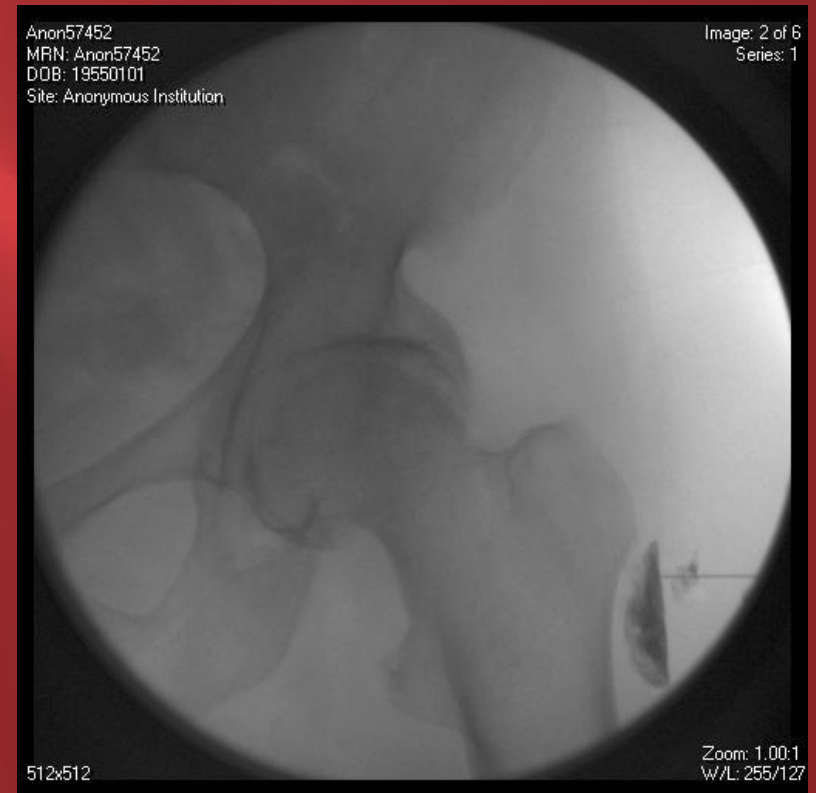

# IT BAND INJECTIONS

## PRE-INJECTION



## POST-INJECTION



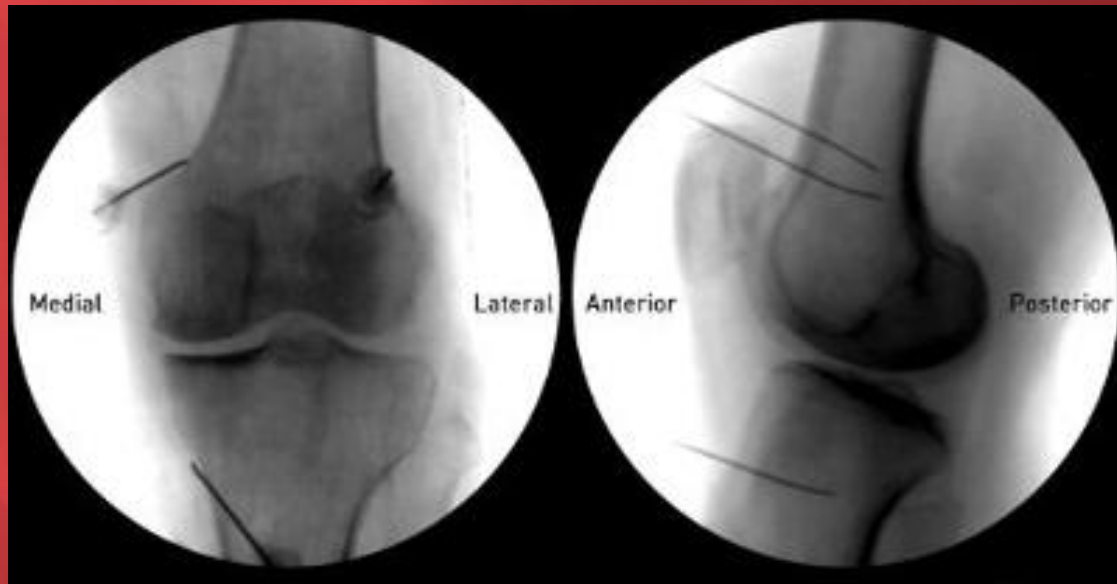# Genicular Nerve Blocks

- ▣ Persistent knee pain after Total Knee Replacement (TKR)
- ▣ Too Young/Old/Sick for TKR
- ▣ Want to hold off having TKR
- ▣ Chronic severe OA pain refractory to other conservative treatments

# Genicular Nerve Blocks

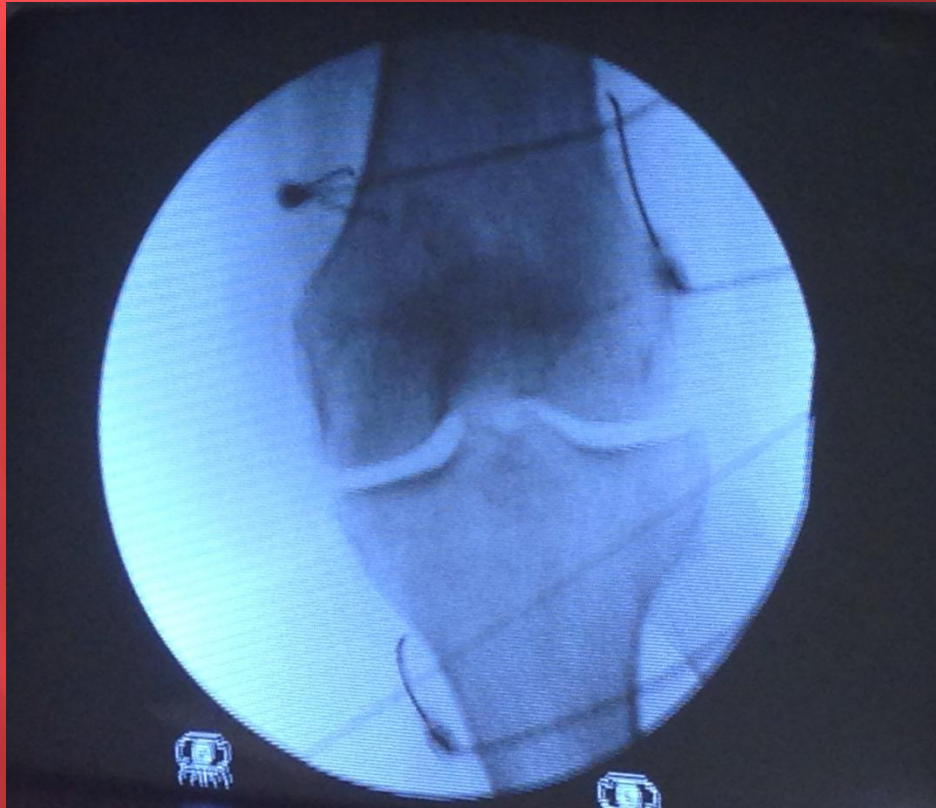
- ▣ This procedure is based on a theory that blocking the nerve supply to a painful area may alleviate pain and restore function.
- ▣ The knee joint is innervated by the articular branches of various nerves, including the femoral, common peroneal, saphenous, tibial, and obturator nerves.
- ▣ These branches around the knee joint are known as genicular nerves.
- ▣ Several genicular nerves can be easily approached with a needle under fluoroscopic guidance. Patients can get a diagnostic genicular ("G Block") nerve block to determine if this will provide adequate relief.

# Genicular Nerve Bloc





# Genicular Nerve Ablation



# Thank You

