

Managing Peri-implantitis

Educational Objectives

Following this unit of instruction, the practitioner should be able to:

1. Understand the etiology and presentation of peri-implantitis.
2. Discuss different methods used to manage peri-implantitis.
3. Understand the limitations of surgical and non-surgical approaches used to manage peri-implantitis.
4. Recognize the importance of searching the available literature to stay current with effective methods to manage peri-implantitis.

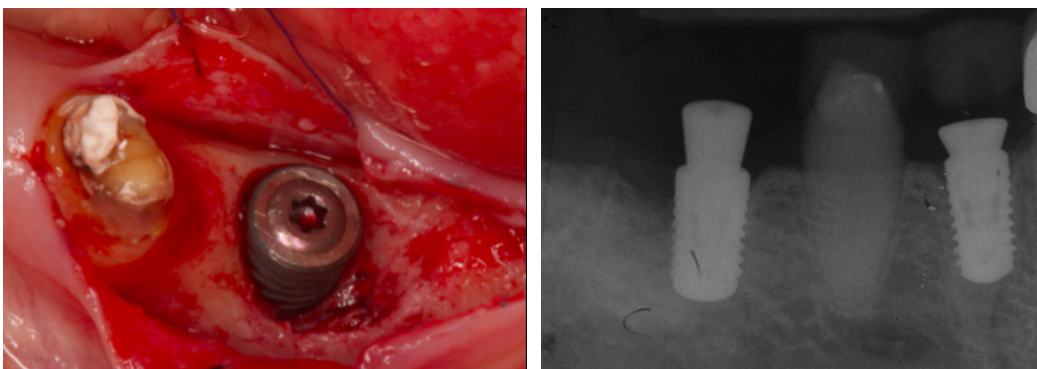
Introduction

Dental implants are often offered as an option to replace missing natural teeth. The predictability of implants has led to increased popularity among both clinicians and patients over the past several decades. Implant placements worldwide have increased exponentially and are now estimated to be about 15 million annually.¹ Much attention has been given over the past decade to inflammatory pathology occurring around implants. Two types of peri-implant diseases have been identified: a) *peri-implant mucositis* - a reversible, inflammatory process in the peri-implant region presenting as reddening, swelling and bleeding on probing without loss of supporting bone,² and; b) *peri-implantitis* - an

inflammatory process resulting in progressive loss of supporting bone around the implant (Figure 1).³

There has been no consensus regarding clearly defined criteria for peri-implantitis, with at least thirteen different definitions being presented. There are also multiple different classifications of the disease. One of the classification systems (Froum and Rosen) classified peri-implantitis into three categories based on pocket depth and bone loss (Table 1).⁴ The reported prevalence of peri-implant mucositis is 43% with a range of 19-65%. Peri-implantitis prevalence is reported at 22% with a range of 1- 47.1%.⁵ The enormous range in these estimates is due to varying case definitions, study designs and population sizes, as well as subjects with different risk profiles.

Figure 1



Clinical and radiographic appearance of Peri-implantitis with loss of supporting bone.

FIRST EDITION

Author Acknowledgements

Namita Khandelwal BDS, MS

Assistant Clinical Professor
College of Dental Medicine
University of New England
Portland, ME

Dr. Khandelwal has no relevant financial relationships to disclose.

The following commentary highlights fundamental and commonly accepted practices on the subject matter. The information is intended as a general overview and is for educational purposes only. This information does not constitute legal advice, which can only be provided by an attorney.

© Metropolitan Life Insurance Company, New York, NY. All materials subject to this copyright may be photocopied for the noncommercial purpose of scientific or educational advancement.

Published August 2016. Expiration date: December 2019. The content of this Guide is subject to change as new scientific information becomes available.

ADA CERP® Continuing Education Recognition Program

MetLife is an ADA CERP Recognized Provider.

ADA CERP is a service of the American Dental Association to assist dental professionals in identifying quality providers of continuing dental education. ADA CERP does not approve or endorse individual courses or instructors, nor does it imply acceptance of credit hours by boards of dentistry.

Concerns or complaints about a CE provider may be directed to the provider or to ADA CERP at www.ada.org/goto/cerp.

Accepted Program Provider FAGD/MAGD
Credit 11/01/12 - 12/31/16.

Address comments to:
dentalquality@MetLife.com
MetLife Dental
Quality Initiatives Program
501 US Highway 22
Bridgewater, NJ 08807

Peri-implantitis demands aggressive management compared to peri-implant mucositis. Hence, this *Quality Resource Guide* will focus on peri-implantitis, its risk factors, prevention and management.

Risk Factors for Peri-implantitis

There are a number of factors that have been implicated in the development of peri-implantitis; however, poor oral hygiene leading to the development of a pathogenic microbial biofilm or plaque is probably the most apparent concern in most of our patients. Incomplete plaque removal around an implant can result initially in the development of peri-implant mucositis.⁶ Peri-implant mucositis represents the soft tissue inflammatory response to bacterial challenge by the microbial biofilm and is considered an important precursor for peri-implantitis.⁷ As we continue to enhance our understanding of the role for maturation of a pathogenic biofilm in developing periodontal disease, we are beginning to see evidence of similar biofilm development on implant surfaces.⁸ Pre-existing peri-implant mucositis without maintenance significantly increases the incidence of peri-implantitis, demonstrating clinical consequences of a maturing pathogenic biofilm.⁹

There appears to be a strong relationship between microbiota in periodontal disease, peri-implant disease and natural teeth. Natural teeth with periodontal disease appear to act as a reservoir for pathogens in partially edentulous patients putting implants in these patients at greater risk of peri-implantitis.^{10,11} Individuals with history of periodontitis demonstrate a higher incidence of peri-implantitis, with deeper probing depths and increase in marginal bone loss.¹² Clinicians need to exert extra caution in the use of implant therapy for patients with a history of periodontal disease, and certainly in those patients with active periodontal disease around remaining natural teeth.¹³

With this well-established cause and effect relationship between poor oral hygiene and peri-implant disease, the role for a preventive maintenance program becomes critical to long-

Table 1 - Classification of Perio-Implantitis⁴

Early	PD ^A ≥ 4mm (bleeding and/or suppuration on probing) ^B Bone loss <25% of implant length ^C
Moderate	probing depth ≥ 6mm (bleeding and/or suppuration on probing) ^B Bone loss 25-50% of implant length ^C
Severe	probing depth ≥ 8mm (bleeding and/or suppuration on probing) ^B Bone loss >50% of implant length ^C

^A Probing Depth

^B Noted on two or more aspects of the implant.

^C Measured on radiographs from the time of definitive prosthesis loading to current radiograph. If not available, the earliest available radiograph following loading should be used.

term implant success. Often oral hygiene and maintenance therapy may be further compromised by complex prosthetic designs. Where possible, both prosthetic designs and maintenance regimens should be adjusted with these factors in mind to enhance the possibility of long-term success.

Apart from microbial biofilm accumulation, various other local and systemic factors have been implicated as risk factors that increase risk of peri-implantitis. Renvert and Quirynen examined the available evidence and listed the following as risk factors for peri-implantitis:¹⁴

Local Factors

- Poor hygiene
- Smoking
- History of periodontitis
- Restorative cement overflow
- Occlusal overload
- Poor restoration design

Systemic Factors

- Diabetes
- Cardiovascular diseases

Systematic reviews suggest peri-implantitis may occur in smokers about four times as often as non-smokers (odds ratios between 3.6-4.6).^{15,16} Another important local factor associated with peri-implantitis is retained cement. Cement overflow may occur during implant crown cementation and act as foreign body, triggering inflammation. Peri-implantitis is seen in 85% of implants that exhibit

incidental cement remnants.¹⁷ Implants with cemented restorations have 3.6 times more risk of peri-implantitis than those with screw retained restorations.¹⁸ Unfortunately, radiographs are unreliable in detecting excess cement and provide little evidence of cement overflow, increasing the need for careful clinical assessment.¹⁹ Occlusal overload remains controversial as a risk factor for peri-implantitis, with studies both supporting and refuting its role in leading to peri-implantitis. While occlusal overload remains questionable as a causative agent, care should be given to assure that it is minimized.²⁰

Peri-implantitis is most prevalent in mandibular posterior regions and least prevalent in the maxillary anterior region.¹⁸ Implants placed in the maxilla have shown a rate of failure three times higher than those placed in the mandible.²¹ This has been attributed to the poorer bone quality in maxilla, especially in posterior regions.²² The bone type at specific sites may also play a role in success of implant. All bone types, except type 2*, have reported almost two times greater risk for early implant failure,²³ and type 4 bone* has shown the greatest failure rate (63%).²⁴

* **Type 1 bone:** almost the entire bone is composed of homogenous compact bone

Type 2 bone: a thick layer of compact bone surrounds a core of dense trabecular bone

Type 3 bone: a thin layer of cortical bone surrounds a core of dense trabecular bone

Type 4 bone: a thin layer of cortical bone surrounds a core of low-density trabecular bone

Apart from local factors, systemic conditions may also play a role in progression of peri-implantitis. In the past, some have stated that implants were contraindicated in diabetic patients.²⁵ However, in the recent years, implants have been successfully placed in patients with poorly controlled diabetes.²⁶ When comparing the clinical outcomes between well and poorly controlled diabetics, little difference was noted in prevalence rate of bleeding on probing, however, the prevalence of bone loss was higher in the poorly controlled group (60% vs. 45%).²⁷ Retrospective analysis reported cardiovascular disease as a risk factor for peri-implantitis (odds ratio 8.7) and a high likelihood of comorbidity.⁶ One of the study's limitations was that cardiovascular disease was self-reported, reducing the reliability of the reported data. Overall, there is limited data demonstrating that cardiovascular disease affects bone loss. Other systemic factors, such as osteoporosis and radiation therapy in head and neck region, can affect osseointegration and are considered as contraindications to implant placement.

Due to multifactorial peri-implant disease model, one should be mindful of possible correlation of local and systemic factors. Biofilm is considered as the primary offending factor responsible for marginal bone loss. Hence, it is important to establish an implant maintenance program that is designed based upon the patient's difficulty in consistently removing plaque from the implant region and the presence of other risk factors. It should be adjusted as necessary.

Diagnostic Criteria for Peri-implantitis

Early detection of peri-implant mucositis progression results in better case management and an increased chance of implant survival. Peri-implant mucositis is a reversible process. Control of local factors can help improve clinical parameters and halt progression to irreversible peri-implantitis.

Important diagnostic criteria for peri-implantitis are bleeding and/or suppuration on probing, with progressively increasing probing depths. It is extremely important to probe the implant region initially to establish a baseline, and then

at each maintenance visit to detect any increases in probing depths. As anatomic factors associated with differing implant designs may greatly alter what would be considered normal probing depths in that specific circumstance, the identification of a change from baseline probing depth serves as a critical indicator. Healthy sulcular depths may vary because of differences in implant systems, depth of abutments, positioning of implant margins relative to adjacent bone levels, as well as surgical and loading protocols.²⁸ Using a reference point on the restoration, probing depth is measured from the base of the implant sulcus to the crest of gingival margin.²⁹ The clinician must remember that the soft tissue attachment to the implant differs from that to natural teeth; lighter probing is encouraged around dental implants than around teeth.³⁰ There is no evidence that the type of probe (metal or plastic) affects probing depth assessment or has any clinical impact on the implant surface. It is more critical to obtain accuracy in probing than be concerned about potential impact to the implant surface. It is also important to consider changes in probing depths as a consequence of marginal tissue inflammation rather than bone loss. Given the altered soft tissue attachment to the implant surface, inflammation in these tissues creates greater disruption of the tissue integrity and may allow the probe tip to penetrate to the bone crest.³¹ Therefore, critical appraisal of the probing needs to consider the baseline measurements were most likely made in the absence of inflammation. Alterations in probing depths need to be considered relative to the level of inflammation present, knowing that the latter circumstance may better reflect the position of the bone crest.

Treatment of Peri-implantitis

Both surgical and non-surgical approaches have been evaluated for the management of peri-implantitis. The treatment approach employed is determined by probing depth and defect characteristics. A non-surgical approach involves surface detoxification using mechanical, chemical, lasers and antibiotic therapy (locally and/or systemically). Surgical approaches include access flap, as well as resective and regenerative surgical techniques.

Non-Surgical Approaches

Implant surface detoxification is a common step for both surgical and non-surgical approaches. The goal of detoxification is to reduce the bacterial load on the implant surface and render it free of bacterial by-products. Often, detoxification is accomplished using periodontal curettes. Curettes used for debridement of the implant surface must be softer than the material comprising the implant. Traditional stainless steel curettes have higher external hardness than titanium and will result in scratches on the implant surface. They should not be used on titanium implants, however they can be safely employed if the implant is made of titanium zirconoxide or titanium oxinitride.³² Titanium-coated curettes are similar in hardness to titanium implants and minimize scratching of the implant surface.³³ Non-metal curettes can successfully remove biofilm from implant and abutment surfaces, and are recommended for titanium implants.³⁴ They are available as plastic, carbon, resin-reinforced and resin-unreinforced. Ultrasonic scalers may also be used to detoxify the implant surface. An ultrasonic scaler with a metal tip has been shown to eliminate bacteria and irregularities from an implant surface more efficiently than one using a plastic tip. Also, use of the plastic tip resulted in same surface irregularities as using the metal tip.³⁵

Air-powder abrasive polishing has been shown to be effective in biofilm removal from an implant surface. Air abrasives containing glycine powder, as opposed to those comprised of sodium bicarbonate powder, are recommended due to effective biofilm removal without any damaging effects on hard and soft tissues.³⁶ Detoxification of the implant surface may also be achieved with application of hydrogen peroxide, EDTA, chlorhexidine, citric acid, saline or the local application of antibiotics. Soaking an implant surface with 3% hydrogen peroxide for one minute demonstrated inactivation of attached bacteria.³⁷

Following surface detoxification, local delivery system using chips were evaluated. Bone matrix chips (*MatrixC*) and chlorhexidine chips (*PerioC*) were compared for six months in sixty patients. Following the therapy, patients with initially deeper probing depth showed a reduction of

2mm in the *PerioC* group and 1.59mm in *MatrixC* group. Minocycline spheres and chlorhexidine gel debridement were compared for a year and showed improvement in plaque indices, pocket depths and bleeding. Minocycline was shown to be effective but to maintain the effectiveness, additional applications might be needed.^{38,39} Use of chlorhexidine in humans has been shown to decrease cell proliferation and reduce collagen synthesis,⁴⁰ hence its use in implant surface detoxification is questioned.

The applications of dental lasers for dental therapy continue to grow. Laser therapy has been suggested for management of peri-implantitis due to its anti-infective and ablative properties. Currently lasers available in the market are: Nd:Yag; carbondioxide; diode, and Er:Yag. Er:Yag is considered to have the most potential for management of peri-implantitis. Along with effective plaque removal, Er:Yag is not absorbed by the titanium surface and its use of water irrigation prevents overheating of bone. Recommended setting for the laser is 100mJ at a frequency of 10Hz for 2 minutes. Higher settings can cause implant surface changes.⁴¹ Comparative studies evaluating use of Er:Yag alone in comparison to surgical and nonsurgical therapy for peri-implantitis did not show any additional benefits of lasers.⁴² Photodynamic therapy, utilizing 630-700nm wavelength of light, has shown reduction in clinical disease parameters for up to six months combined with application of minocycline.⁴²

Implantoplasty (reshaping and/or smoothing the implant surface) may be completed with a combination of diamond and carborundum burs, or carborundum burs alone.³⁴ The goal of implantoplasty is a smooth implant surface that enables better maintenance by the patient and/or the clinician. Implantoplasty may result in soft tissue loss, creating esthetic concerns and potentially leading to increased food impaction in interproximal spaces. Implantoplasty requires minimal implant surface removal hence implant weakening does not appear to be an issue. The risks and benefits of the procedure should be thoroughly discussed with the patient, explaining the potential adverse and irreversible outcomes. There is limited evidence supporting its application and it should only be employed as an adjunct to other therapeutic measures.

Surgical Approaches

A nonsurgical approach is recommended in shallow defects to maintain the height of the soft tissue margins.⁴⁴ Non-surgical therapies, however, may offer limited access in some regions and surgical therapy may be necessary to enhance the opportunity for long-term stabilization. The surgical technique employed depends on defect morphology and typically involves an access flap and debridement/detoxification, followed by resective and/or regenerative procedures. Schwarz et al. demonstrated that a combination of resective and regenerative surgical techniques are usually more effective.⁴⁵ Defect morphology can impact the treatment outcome following regenerative therapy.⁴⁶

The objective of an access flap and debridement is to remove the inflamed tissue around the implant, allowing access to the osseous defect. Implant surface detoxification, as discussed earlier, can be achieved using chemical, mechanical and/or lasers following tissue reflection. In non-esthetic regions with a shallow, one-walled intrabony defect, effective therapy consists of implantoplasty and osteoplasty followed by apically repositioning of the soft tissue flap. This will result in tissue recession and a region more conducive to successful maintenance.

Multiple studies have reported various surgical approaches based on defect morphology, irrigants, employing single or multiple grafting materials and, use of resorbable or non-resorbable membrane. There is no single surgical therapy that is considered superior over other. Surgical therapy includes elevation of mucoperiosteal flap, access to implant surface and defect by removal of granulation tissue, implant surface decontamination or modification, resective or regenerative therapy and post-therapy systemic antibiotic administration.⁴⁷ Implant removal should be considered if they are mobile with radiographic bone loss extending around the apex. As surgical therapies are complex procedures, it is highly recommended that they be performed by skilled clinicians with surgical training in periodontal therapies. Also, with no clear evidence supporting one specific therapy, literature should be reviewed consistently for strong evidence to support surgical approaches.

Conclusion

A number of therapy approaches have demonstrated the potential to successfully treat peri-implantitis (Table 2). Techniques for the management of peri-implantitis are still evolving. Many protocols have been tried, with some showing promising clinical results. However, there is no protocol proven to be superior over other. At this time, it appears that research supports the following conclusions:

1. Peri-implant mucositis acts as a precursor for peri-implantitis
2. Surface detoxification, along with modification of the implant and the tissue architecture to facilitate maintenance, are the most important steps in management of all peri-implantitis lesions.
3. Lasers do not demonstrate additional benefit over other detoxification techniques.
4. Defect morphology dictates type of surgical approach that should be utilized.

Table 2 - Therapeutic Options

Non-Surgical	Surgical
<ul style="list-style-type: none"> • Surface detoxification • Curettes • Airpowder abrasive • Local drug delivery • Lasers • Implantoplasty 	<ul style="list-style-type: none"> • Resective • Regenerative • Combination

REFERENCES

1. Machtei EE. Treatment Alternatives to Negotiate Peri-Implantitis. *Adv Med* 2014;2014:487903.
2. Mombelli A, Muller N, Cionca N. The epidemiology of peri-implantitis. *Clin Oral Implants Res* 2012;23 Suppl6:67-76.
3. Lindhe J, Meyle J, Group DoEWoP. Peri-implant diseases: Consensus Report of the Sixth European Workshop on Periodontology. *J Clin Periodontol* 2008;35:282-285.
4. Froum SJ, Rosen PS. A proposed classification for peri-implantitis. *Int J Periodontics Restorative Dent* 2012;32:533-540.
5. Derks J, Tomasi C. Peri-implant health and disease. A systematic review of current epidemiology. *J Clin Periodontol* 2015;42 Suppl16:S158-171.
6. Renvert, S. & Polyzois, I. (2014) Risk indicators for peri-implant mucositis: a systematic literature review. *Journal of Clinical Periodontology* 42 Suppl16: S172–S186.
7. Lang NP, Berglundh T. Periimplant diseases: where are we now?- Consensus of the Seventh European Workshop on Periodontology. *J Clin Periodontol* 2011; 38 Suppl11:178=181.
8. Hajishengallis G.The inflammalophilic character of ther periodontitis- associated microbiota. *Mol Oral Microbiol* 2014;Dec 29(6):248-57
9. Costa FO, Takenaka-Martinez S, Cota LOM, Ferreira SD, Silva GLM, Costa JE, Peri-implant disease in subjects with and without preventive maintenance: a 5-year follow-up. *J Clin Periodontol* 2012;39:173–181.
10. Botero, J.E., Gonzalez, A.M., Mercado, R.A., Olave, G. & Contreras, A. Subgingival microbiota in peri-implant mucosa lesions and adjacent teeth in partially edentulous patients. *Journal of Periodontology* 2005;76:1490–1495.
11. Maruyama, N., Maruyama, F., Takeuchi, Y., Aika- wa, C., Izumi, Y. & Nakagawa, I. Intraindividual variation in core microbiota in peri- implantitis and periodontitis. *Scientific Reports* 2014;4:6602.
12. Rocuzzo, M., Bonino, F., Aglietta, M. & Dalmasso, P. Ten-year results of a three arms prospective cohort study on implants in periodontally compromised patients. Part 2: Clinical results. *Clinical Oral Implants Research* 2012;23:389–395.
13. Heitz-Mayfield, L.J. & Lang, N.P. Comparative biology of chronic and aggressive periodontitis vs. Peri-implantitis. *Periodontology* 2000 2010;53:167–181.
14. Renvert S, Quirynen M. Risk indicators for peri-implantitis. A narrative review. *Clin Oral Implants Res* 2015;26 Suppl11:15-44.
15. Heitz-Mayfield, L. J. & Huynh-Ba, G. History of treated periodontitis and smoking as risk for implant therapy. *International Journal of Oral and Maxillofacial Implants* 2010;24(suppl):39–68.
16. Strietzel FP, Reichart PA, Kale A, Kulkarni M, Wegner B, Kuchler I. Smoking interferes with the prognosis of dental implant treatment: A systematic review and meta-analysis. *J Clin Periodontol* 2007;34:523-544.
17. Linkevicius, T., Puisys, A., Vindasiute, E., Linke- viciene, L. & Apse, P. Does residual cement around implant-supported restorations cause peri-implant disease? A retrospective case analysis. *Clinical Oral Implants Research* 2013b;24:1179–1184.
18. Dalago HR, Schuldt Filho G, Rodrigues MA, Renvert S, Bianchini MA. Risk indicators Risk indicators for peri-implantitis. A cross sectional study with 916 patients. *Clinical Oral Implants Research* 2016;00:1-7.doi: 10.1111/clr.12772
19. Linkevicius, T., Vindasiute, E., Puisys, A., Linkeviciene, L., Maslova, N. & Puriene, A. The influence of the cementation margin position on the amount of undetected cement. A prospective clinical study. *Clinical Oral Implants Research* 2013a;24:71–76.
20. Hsu, Y.T., Fu, J.H., Al-Hezaimi, K. & Wang, H.L. Biomechanical implant treatment complications: a systematic review of clinical studies of implants with at least 1 year of functional loading. *International Journal of Oral and Maxillofacial Implants* 2012; 27:894–904.
21. Esposito M, Hirsch JM, Lekholm U, Thomsen P. Biological factors contributing to failures of osseointegrated oral implant. (I). Success criteria and epidemiology. *Eur J Oral Sci* 1998; 106(1):527-51.
22. Chrcanovic BR, Albrektsson T, Wennerberg A. Reasons for failures of oral implants. *J Oral Rehabil* 2014; 41(6):443-76.
23. Noguero B, Munoz R, Mesa F, de Dios Luna J, O'Valle F. Early implant failure. Prognostic capacity of Periotest: retrospective study of a large sample. *Clin Oral Impants Res* 2006; 17(4):459-64.
24. Hermann I, Lekholm U, Holm S, Kultje C. Evaluation of patient and implant characteristics as potential prognostic factors for oral implant failures. *Int J Oral Maxillofac Implants* 2005; 20(2):220-30.
25. Takeshita, F., Iyama, S., Ayukawa, Y., Kido, MA, Murai, K. & Suetsugu, T. The effects of diabetes on the interface between hydroxyapatite implants and bone in rat tibia. *Journal of Periodontology* 1997; 68:180–185.

26. Oates, T.W., Dowell, S., Robinson, M. & McMahan, C.A. Glycemic control and implant stabilization in type 2 diabetes mellitus. *Journal of Dental Research* 2009;88:367–371.
27. Venza I, Visalli M, Cucinotta M, De Grazia G, Teti D, Venza M. Proinflammatory gene expression at chronic periodontitis and peri-implantitis sites in patients with or without type 2 diabetes. *J Periodontol*. 2010; 81(1):99-108.
28. Cochran DL, Hermann JS, Schenk RK, Higginbottom FL, Buser D. Biologic width around titanium implants. A histometric analysis of the implantogingival junction around unloaded and loaded nonsubmerged implants in the canine mandible. *J Periodontol* 1997;68:186–198.
29. Academy report: Peri-implant mucositis and Peri-implantitis: A current understanding of their diagnoses and clinical implications. *J of Periodontol* 2013; 84(4):436-443.
30. Etter TH, Hakanson I, Lang NP, Trejo PM, Caffesse RG. Healing after standardized clinical probing of the perimplant soft tissue seal: A histomorphometric study in dogs. *Clin Oral Implants Res* 2002;13:571–580.
31. Schou S, Holmstrup P, Stoltze K, Hjoirting-Hansen E, Fiehn NE, Skovgaard LT. Probing around implants and teeth with healthy or inflamed peri-implant mucosa/gingiva. A histologic comparison in cynomolgus monkeys (*Macaca fascicularis*). *Clinical Oral Implant Research* 2002;Apr 13(2):113-26
32. Schenk G, Flemmig TF, Betz T, Reuther J, Klaiber B. Controlled local delivery of tetracycline HCl in the treatment of periimplant mucosal hyperplasia and mucositis. A controlled case series. *Clin Oral Implants Res* 1997;8:427-433.
33. Hallstrom H, Persson GR, Lindgren S, Olofsson M, Renvert S. Systemic antibiotics and debridement of peri-implant mucositis. A randomized clinical trial. *J Clin Periodontol* 2012;39:574-581.
34. Valderrama P, Wilson TG, Jr. Detoxification of implant surfaces affected by peri-implant disease: an overview of surgical methods. *Int J Dent* 2013;2013:740680.
35. Park JB, Jang YJ, Koh M, Choi BK, Kim KK, Ko Y. In vitro analysis of the efficacy of ultrasonic scalers and a toothbrush for removing bacteria from resorbable blast material titanium disks. *J Periodontol* 2013;84:1191-1198.
36. Petersilka GJ, Steinmann D, Haberlein I, Heinecke A, Flemmig TF. Subgingival plaque removal in buccal and lingual sites using a novel low abrasive air-polishing powder. *J Clin Periodontol* 2003;30:328-333.
37. Gosau M, Hahnel S, Schwarz F, Gerlach T, Reichert TE, Burgers R. Effect of six different peri-implantitis disinfection methods on in vivo human oral biofilm. *Clin Oral Implants Res* 2010;21:866-872.
38. Machtei EE, Frankenthal S, Levi G, Elimelech R, Shoshani E, Rosenfeld O, et al.. Treatment of peri-implantitis using multiple applications of chlorhexidine chips: a double-blind, randomized multi-centre clinical trial. *J Clin Periodontol* 2012;39:1198-1205.
39. Renvert S, Lessem J, Dahlen G, Lindahl C, Svensson M. Topical minocycline microspheres versus topical chlorhexidine gel as an adjunct to mechanical debridement of incipient peri-implant infections: a randomized clinical trial. *J Clin Periodontol* 2006;33:362-369.
40. Lee TH, Hu CC, Lee SS, Chou MY, Chang YC. Cytotoxicity of chlorhexidine on human osteoblastic cells is related to intracellular glutathione levels. *Int Endod J* 2010;43:430-435.
41. Kim JH, Herr Y, Chung Jh, et al. The effect of erbium-doped: yttrium, aluminium and garnet laser irradiation on the surface microstructure and roughness of double acid-etched implants. *J Periodontal Implant Sci* 2011;41(5):234-41.
42. Fu JH, Wang HL. Can Periimplantitis Be Treated? *Dent Clin North Am* 2015;59:951-980.
43. Schar D, Ramseier CA, Eick S, Arweiler NB, Sculean A, Salvi GE. Anti-infective therapy of peri-implantitis with adjunctive local drug delivery or photodynamic therapy: six-month outcomes of a prospective randomized clinical trial. *Clin Oral Implants Res* 2013;24:104-110.
44. Figuero E, Graziani F, Sanz I, Herrera D, Sanz M. Management of peri-implant mucositis and peri-implantitis. *Periodontol* 2000 2014;66:255-273.
45. Schwarz F, Sahm N, Becker J. Combined surgical therapy of advanced peri-implantitis lesions with concomitant soft tissue volume augmentation. A case series. *Clin Oral Implants Res* 2014;25:132-136.
46. Schwarz F, Sahm N, Schwarz K, Becker J. Impact of defect configuration on the clinical outcome following surgical regenerative therapy of peri-implantitis. *J Clin Periodontol* 2010;37:449-455.
47. Heitz-Mayfield LJ, Needleman I, Salvi GE, Pjetursson BE. Consensus statements and clinical recommendations for prevention and management of biologic and technical implant complications. *Int J Oral Maxillofac Implants*. 2014;Suppl29:346-350

POST-TEST

Internet Users: This page is intended to assist you in fast and accurate testing when completing the “Online Exam.” We suggest reviewing the questions and then circling your answers on this page prior to completing the online exam.

(1.0 CE Credit Contact Hour) Please circle the correct answer. 70% equals passing grade.

- 1. Peri-implantitis differs from peri-implant mucositis by**
 - a. Deep probing depths
 - b. Bleeding on probing
 - c. Loss of supporting bone
 - d. Swelling around restored implant
- 2. Identify least potential risk factors in the etiology of peri-implantitis could be all of the following, EXCEPT:**
 - a. A screw retained implant crown
 - b. Diabetes
 - c. Poor oral hygiene
 - d. Occlusal overload
- 3. Surface detoxification is common step for surgical and non-surgical approaches for treating peri-implantitis.**
 - a. True
 - b. False
- 4. Implants should be managed for peri-implantitis in all of the cases, EXCEPT:**
 - a. Near anatomic landmark
 - b. Key restorative position
 - c. Intrabony defects
 - d. Mobility
- 5. All of the following are true about implantoplasty, EXCEPT:**
 - a. Compromises esthetics
 - b. Enables maintenance
 - c. Stimulates re-osseointegration
 - d. Results in soft tissue loss
- 6. Selection of a peri-implantitis treatment approach depends on:**
 - a. Defect morphology
 - b. Probing depth
 - c. Radiographic bone loss in relation to implant length
 - d. All of the above
- 7. During surgical management of peri-implantitis, implants must be always submerged.**
 - a. True
 - b. False
- 8. The proposed Er:Yag laser setting for peri-implantitis management is:**
 - a. 100mJ/10Hz
 - b. 50mJ/15Hz
 - c. 120mJ/10Hz
 - d. 100mJ/20Hz
- 9. In a defect with less than 4mm probing depth, bleeding on probing, 10-15% bone loss along the implant length and systemically healthy patient, the following is approach to treating peri-implantitis would be generally recommended:**
 - a. Surgical approach
 - b. Non-surgical approach
 - c. Combination of surgical and non-surgical therapy
 - d. No treatment
- 10. Access flaps allow:**
 - a. Removal of inflamed tissue around the implant
 - b. Access to peri-implantitis defect
 - c. All of the above
 - d. None of the above

